

中文題目：Oxacillin 誘發之嗜血症候群

英文題目：Oxacillin induced hemophagocytosis

作者：林子閔¹ 李垣樟¹ 林宜君¹ 劉欣怡¹

服務單位：台北醫學大學附設醫院內科¹

Abstract:

Hemophagocytic syndrome (HPS) is a severe illness, occurring with fever, hepatosplenomegaly, and pancytopenia and is characterized by disordered and uncontrolled macrophage activation resulting in phagocytosis of mature and precursors blood cells. Apart from occurring in children as a familial disease, HPS occurs in adults in association with malignant neoplasm, often a peripheral T or NK cell lymphoma, and in both as a secondary event in the course of acute infection, generally of viral etiology or triggered by other causes not always identified. The outcome of HPS is extremely variable: it can behave as a transitory self-limited disease and recover spontaneously or disappear once the primary cause has been treated, or it can progress toward a fatal outcome in a very short time; thus, its prognosis is strictly dependent on the underlying disease. We reported a case of hemophagocytosis in the setting of severe drug hypersensitivity syndrome related to Oxacillin.

Introduction:

Reactive hemophagocytic syndrome has various causes. Drug-induced hypersensitivity syndrome, also called drug rash with eosinophilia and systemic symptoms (DRESS), shares many of the characteristics of adult-onset Still's disease, has also been associated hemophagocytosis.

Case Report:

A 56-year-old male denied any systemic disease. He developed neck pain and tenderness with limited range of motion for 1 week. It accompanied by upper limbs weakness and numbness. Later acute urine retention and lower limb weakness appeared. MRI revealed epidural abscess of C5-C6. He received laminectomy of C5-6 and hemilaminectomy of C4. Antibiotics with Rocephin and oxacillin were given for infection control. The pus culture showed staphylococcus aureus (OSSA). After therapy, patient's muscle power recovery to 3-4, but only upper limbs. Then, whole spine MRI was performed again and revealed residual C5-6 epidural abscess with osteomyelitis and cord compression. Steroid was added for treatment. Emergent operation of anterior cervical discsectomy was performed. The patient was continued to be treated with oxacillin. But fever flared up and pancytopenia with skin rash were noted. Oxacillin was discontinued due to suspicion of drug allergy and steroid was given. Antibiotics was shifted to Teicoplanin for staphylococcus aureus osteomyelitis.

But high fever persisted. Steroid and anti-histamine were used for drug hypersensitivity. Lab data revealed GOT:1133,GPT:3202 and drug induced acute hepatitis was noted. FFP ,PLT and albumin transfusion were suggested for acute fulminant hepatitis. TRALI(transfusion related acute lung injury) and acute pulmonary edema were noted after transfusion and diuretic and parenteral steroid were given again. Gradual improvement of dyspnea and O2 saturation were seen. Follow up liver function revealed thrombocytopenia and PH was transfused. We discontinued Teicoplanin and started Meropenem and Sulbactam. He was transferred to MICU due to progression of pneumonia with respiratory failure s/p E-T + MV. Bone marrow aspiration study showed hemophagocytosis. Abdominal tapping was done for ascites drainage. Chest CT was done and PCP was suspected. Antibiotics shifted to Sulfamethoxazole/Trimethoprim.. However, progression of CXR and poor saturation were noted. ARDS pattern was noted and shock developed. For cardiopulmonary support, ECMO was used and CVVH was given for acidosis and oliguria. Because of persistent GI bleeding, NPO with PPI was given and blood transfusion was given. Neurology was consulted for seizure. Dopamine and Levophed were used for shock. However, clinical condition worsen even treatment. Poor condition and prognosis were told to his family and his family decided to sign DNR. The patient was expired.

Discussion:

The patient presented with the classic symptomatology of drug hypersensitivity syndrome: abrupt onset of fever 9 to 10 days after beginning the drug, with exanthema, cervical lymphadenopathies, and cytolysis. Interestingly, these symptoms were characterized by pancytopenia, which is not a usual feature of the syndrome . In the same manner, these symptoms strongly suggested hemophagocytosis, which was observed in this case.

The mechanisms of cytopenias in drug hypersensitivity syndrome are unknown. Cell destruction by cytotoxic antibodies and a reversible depression of stem cell activity with myeloid maturation blockade have been suggested. The occurrence of hemophagocytosis is possible because drug hypersensitivity syndrome may lead to a systemic inflammatory response, with activation of macrophages that produce inflammatory cytokines. Hemophagocytosis is probably underdiagnosed because both syndromes share nonspecific symptoms, bone marrow cytology is usually not required in a characteristic drug hypersensitivity syndrome, and hemophagocytosis pictures can be missed on bone marrow aspiration.

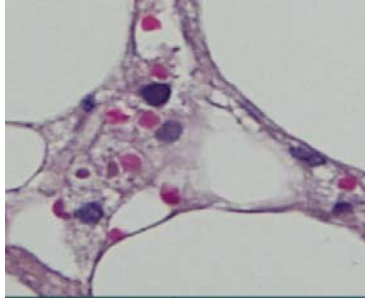


Figure 1