

中文題目：散播性隱球菌感染在非 HIV 感染患者之多樣表現

英文題目：Disseminated cryptococcal infection mimicking lung cancer and cerebral infarction in HIV-seronegative patient

作者：王薪惠<sup>1</sup> 盧柏樑<sup>2</sup> 陳怡庭<sup>3</sup>

服務單位：高雄醫學大學附設中和紀念醫院內科部<sup>1</sup> 高雄醫學大學附設中和紀念醫院感染內科<sup>2</sup> 高雄醫學大學附設中和紀念醫院病理科<sup>3</sup>

**Introduction:** Cryptococcosis is usually caused by *Cryptococcus neoformans* or *Cryptococcus gattii* in immunocompromised patient, especially in HIV-positive patient. Pulmonary and central nervous system are the most frequent infection sites. Herein we presented a case of HIV-seronegative patient with disseminated Cryptococcal infection.

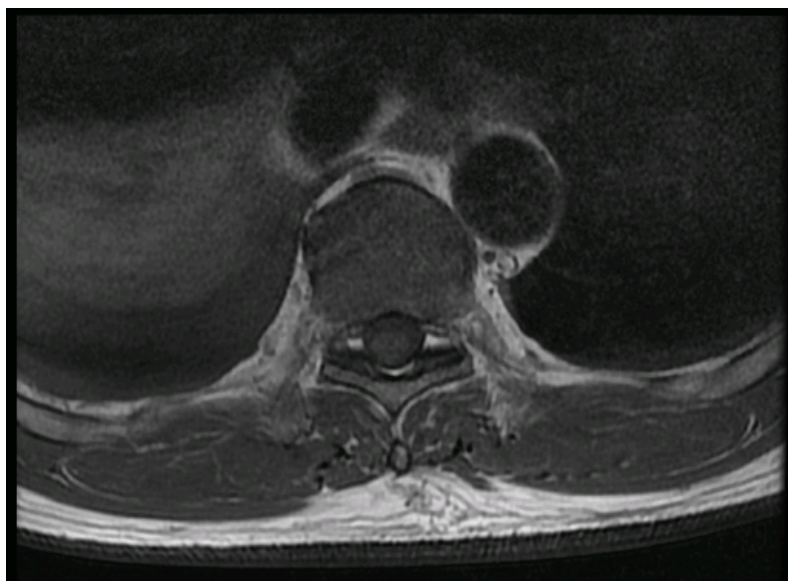
**Case report:** A 58-year-old man visited our neurology out-patient department for progressive bilateral lower leg weakness. The initial diagnosis was ischemic stroke. However, the lower leg weakness and numbness progressed after treatment. Brain MRI only showed old lacunar infarction. T-L spine MRI revealed intramedullary tumor at T9, T10 (Fig.1). There was no fever, shaking chills or intolerable lower back pain. He then received tumor resection and discectomy. The pathologist found round-to-ovoid, translucent fungal spores, which was enhanced by GMS and PAS stain (Fig.2-3). The final pathologic diagnosis was intramedullary Cryptococcal infection. Besides, the blood culture and tissue culture were negative. Serum *Cryptococcus neoformans* and HIV test were also negative.

This patient has diabetes mellitus and history of stage I renal cell carcinoma post right nephrectomy 5 years ago, without recurrence. He was a truck driver, lived in downtown, and denied pigeon contact history. He has been well until 6 months ago. Nodular lesion at right lower lung field was noted on his chest film. The diagnosis after Chest CT survey was lung cancer. He then received right lower lung lobectomy. However, the final pathology was cryptococcosis with granulomatous inflammation, and the lymph nodes were negative for malignancy. He did not receive anti-fungal treatment after the surgery. During this admission, disseminated cryptococcal infection was diagnosed, and the patient received liposomal Amphotericin B and Flucytosine combined therapy for 4 weeks, and then keep oral fluconazole treatment at out-patient depart follow up.

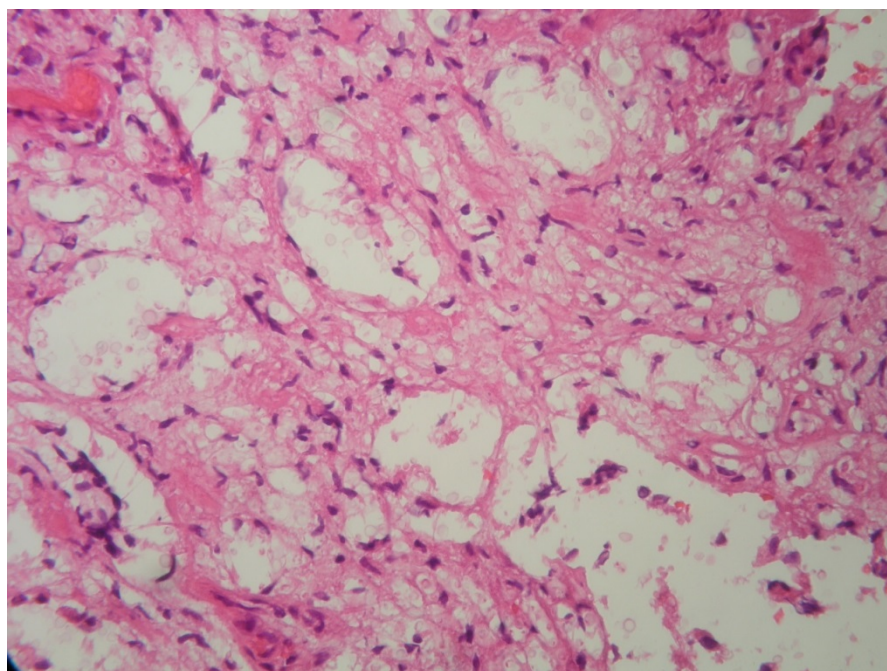
**Discussion:** Cryptococcal infection is likely to be subclinical, asymptomatic initially in immunocompetent patients who have been exposed to *Cryptococcus neoformans* and may become symptomatic when the host immune system becomes

compromised. Pulmonary infection is usually caused by inhalation the spore of fungus or poorly encapsulated yeast. For its possibility to disseminate to central nervous system and other sites, lumbar puncture is suggested for patients with pulmonary cryptococcosis. However, immunocompetent patient without neurologic symptoms and low serum cryptococcal antigen titer may not receive lumbar puncture for low probability of disseminated disease. In a large cohort of HIV-negative patient with pulmonary cryptococcal infection, about one-third patient had disseminated disease, especially in those who had cirrhosis, headache, weight loss, fever, altered consciousness and receiving high-dose corticosteroids [1 ]. Some patients with pulmonary cryptococcoma recovered spontaneously. Cryptococcal bone disease is rare and count for about 5% of systemic cryptococcal infection. However, osteomyelitis can be the first presentation of disseminated cryptococcal infection. There is no absolute treatment duration for cryptococcal osteomyelitis in current treatment guideline. 18-months treatment for vertebral cryptococcal infection was reported [2 ]. In our case, the initial presentation mimicked lung neoplasm and there was no significant neurologic deficiency until he started to have progressive lower leg weakness, which was thought to be cerebral infarction. His serum Cryptococci neoformans and HIV test were also negative. The patient had induction treatment with liposomal Amphotericin B and Flucytosine, and then consolidation therapy with Fluconazole for disseminated cryptococcal infection. However, there is no absolute guide to maintenance treatment duration. For current treatment guideline only separates cryptococcal infection into meningeal and non-meningeal infection, no specific suggestion on cryptococcal bone infection, especially for maintenance treatment. This remains uncertain and may need further study. For its various presentations, diagnosis of extrapulmonary cryptococcal infection in HIV-negative patient is also a challenge.

**Fig.1:** L-spine MRI, T2 FSE, small nodular lesion

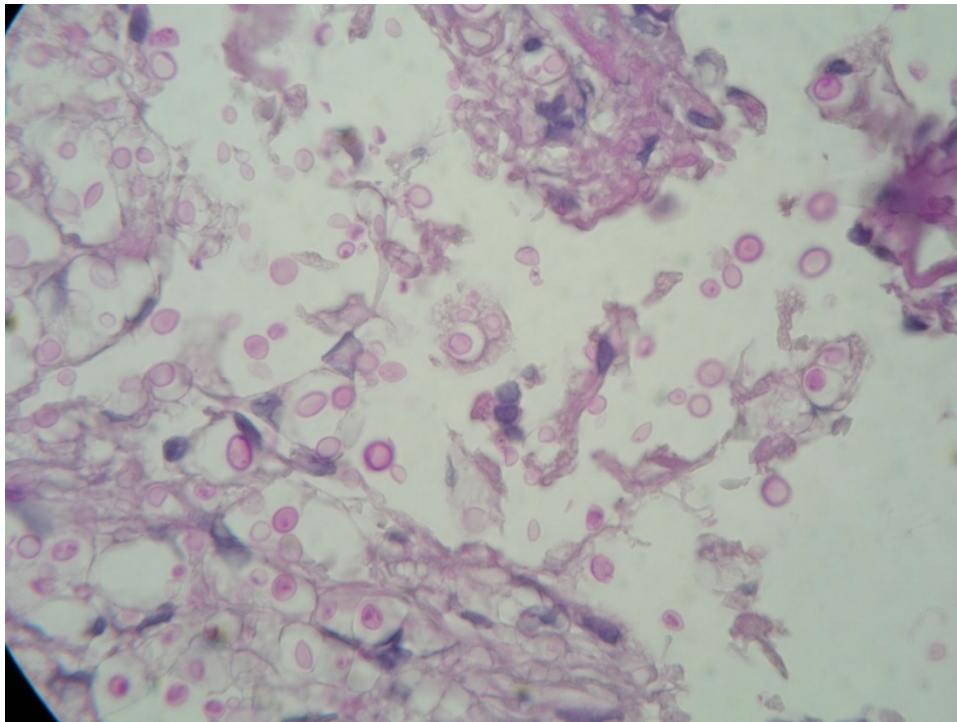


**Fig.2:** H&E stain shows round-to-ovoid shaped fungal



spores.

**Fig.3:** PAS stain of the intramedullary tissue. There are encapsulated spores and budding yeast.



References:

1.

Baddley, J. W., et al. (2008). "Pulmonary cryptococcosis in patients without HIV infection: factors associated with disseminated disease." *Eur J Clin Microbiol Infect Dis* **27**(10): 937-943.

2.

Nankeu, S., et al. (2012). "Disseminated cryptococcosis revealed by vertebral osteomyelitis in an immunocompetent patient." *Joint Bone Spine* **79**(6): 629-631.