

中文題目:皮膚交感神經活性在心律不整以及急性心肌梗塞中的角色

英文題目:The role of skin sympathetic nerve activity in cardiac arrhythmia and acute myocardial infarction

作者:林宗翰, 蔡維中, 顏學偉

服務單位:高雄醫學大學附設醫院內科部心臟血管內科

## **Introduction**

A wealth of evidence supports the widely held belief that sympathetic nervous system activity (SNSA) participates in the genesis of cardiac arrhythmia and also had interactions in the arrhythmias associated with myocardial infarction. According to previous clinical study, skin sympathetic nerve activity (SKNA) is detectable using conventional ECG electrodes and can be used to estimate cardiac sympathetic tone.<sup>1</sup> Here we presented a case with ST-segment elevation myocardial infarction (STEMI), ventricular arrhythmias and high SKNA.

## **Case presentation**

A 50-year-old man who had underlying diabetes mellitus visited Emergency Department due to persistent chest tightness and shortness of breath. 12-lead electrocardiography showed inferior STEMI .

Primary percutaneous coronary intervention (PCI) was done with a bare metal stent implanted in right coronary artery. We had recorded the SKNA during the PCI and in the following days after the procedure. The series SKNA activations were noticed right before ventricular arrhythmias (figure 1). We found the SKNA decreased when coronary flow restored after the PCI and continuously decreased when the patient stayed in the coronary care unit (CCU) (table 1).

## SKNA activities precede NSVT

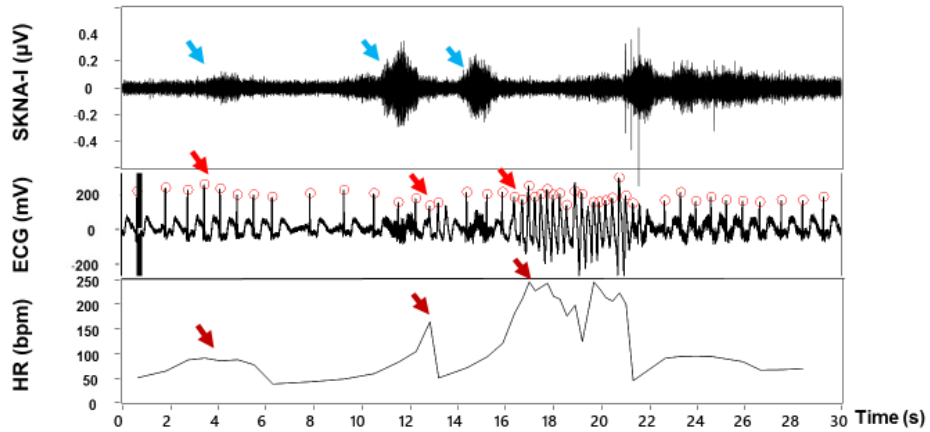


Figure 1. SKNA activations right before the ventricular arrhythmias.

SKNA (uV)	Day1 (PCI)	Day2	Day3
	$1.56 \pm 0.31$	$0.69 \pm 0.04$	$0.73 \pm 0.07$

Table 1. The SKNA continuously decreased after PCI when the patient stayed in CCU.

### Discussion

Significant advances have been made in the understanding of the relationship between sympathetic nerve activity and cardiac arrhythmias.<sup>2, 3</sup> SKNA is detectable using conventional ECG electrodes and can be used to estimate cardiac sympathetic tone. Because the left stellate ganglion nerve activity (SGNA) is known to trigger cardiac arrhythmias,<sup>4</sup> it is possible that SKNA can also be used for arrhythmia prediction.<sup>5</sup>

The case presented here is a patient with STEMI who received primary PCI and the SKNA was recorded simultaneously. During the PCI, non-sustained ventricular tachycardias preceded by SKNA activation were found, and the SKNA decreased after coronary flow restored (TIMI 3 flow) (figure 2). The SKNA continuously decreased after the PCI and during the stay of CCU.

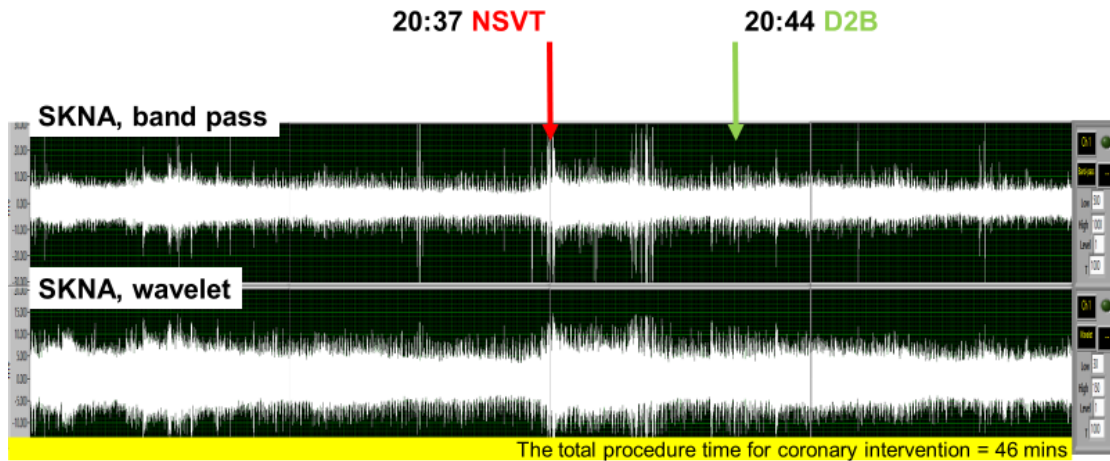


Figure 2. The SKNA decreased after coronary flow restored.

D2B, door to balloon time (TIMI 3 coronary flow); NSVT, non-sustained ventricular tachycardia

### Conclusions

We demonstrate an interesting case with STEMI and ventricular arrhythmias with high SKNA detected. SKNA might be useful to predict the ventricular arrhythmias in myocardial infarction patients.

### References

1. Everett THt, Doytchinova A, Cha YM, Chen PS. Recording sympathetic nerve activity from the skin. Trends in cardiovascular medicine Oct 2017;27:463-472.
2. Shen MJ, Zipes DP. Role of the autonomic nervous system in modulating cardiac arrhythmias. Circulation research Mar 14 2014;114:1004-1021.
3. Ng GA. Neuro-cardiac interaction in malignant ventricular arrhythmia and sudden cardiac death. Autonomic neuroscience : basic & clinical Aug 2016;199:66-79.
4. Zhou S, Jung BC, Tan AY, Trang VQ, Gholmieh G, Han SW, Lin SF, Fishbein MC, Chen PS, Chen LS. Spontaneous stellate ganglion nerve activity and ventricular arrhythmia in a canine model of sudden death. Heart rhythm : the official journal of the Heart Rhythm Society Jan 2008;5:131-139.
5. Doytchinova A, Hassel JL, Yuan Y, et al. Simultaneous noninvasive recording of skin sympathetic nerve activity and electrocardiogram. Heart rhythm : the official journal of the Heart Rhythm Society Sep 23 2016.