

中文題目：一個因為食道異物卡七天造成急性成人上呼吸道阻塞的罕見案例

英文題目：A rare case of adult acute upper airway obstruction due to prolong esophageal foreign body for seven days

作者：陳蕙君<sup>1</sup> 洪明潤<sup>1</sup> 周宜平<sup>1,2</sup> 吳宗儒<sup>1</sup>

服務單位：1 高雄市立民生醫院內科部; 2 高雄榮民總醫院胸腔外科

**Introduction** A 27 years old psychiatric woman was brought to our hospital for upper airway infection. Soon acute upper airway obstruction was noted and intubation was done. Prolong esophageal foreign body ingestion for seven days inducing acute upper airway obstruction was found. Life saving cervical esophagoectomy was done to remove the foreign body.

#### **Case report:**

The 27 years old psychiatric woman was brought to our hospital for upper airway infection. Soon stridor and bilateral decreased breath sound was noted. Intubation was done immediately. After taking chest X ray, a foreign body was noted (figure 1). A same shape foreign body in the same position seven days ago was found (figure 2). We arranged chest computed tomography and the radiopaque foreign body in esophagus was noted (figure 3). After life-saving neck esophagoectomy to remove the foreign body (figure 4).

#### **Discussion:**

Acute upper airway obstruction due to esophageal foreign body ingestion is rare in adults, mostly in psychiatric patients. Upper airway obstruction may mimic upper respiratory tract symptoms which lead to delayed diagnosis. This is a rare case of adult acute upper airway obstruction caused by prolong esophageal foreign body aspiration for seven days.

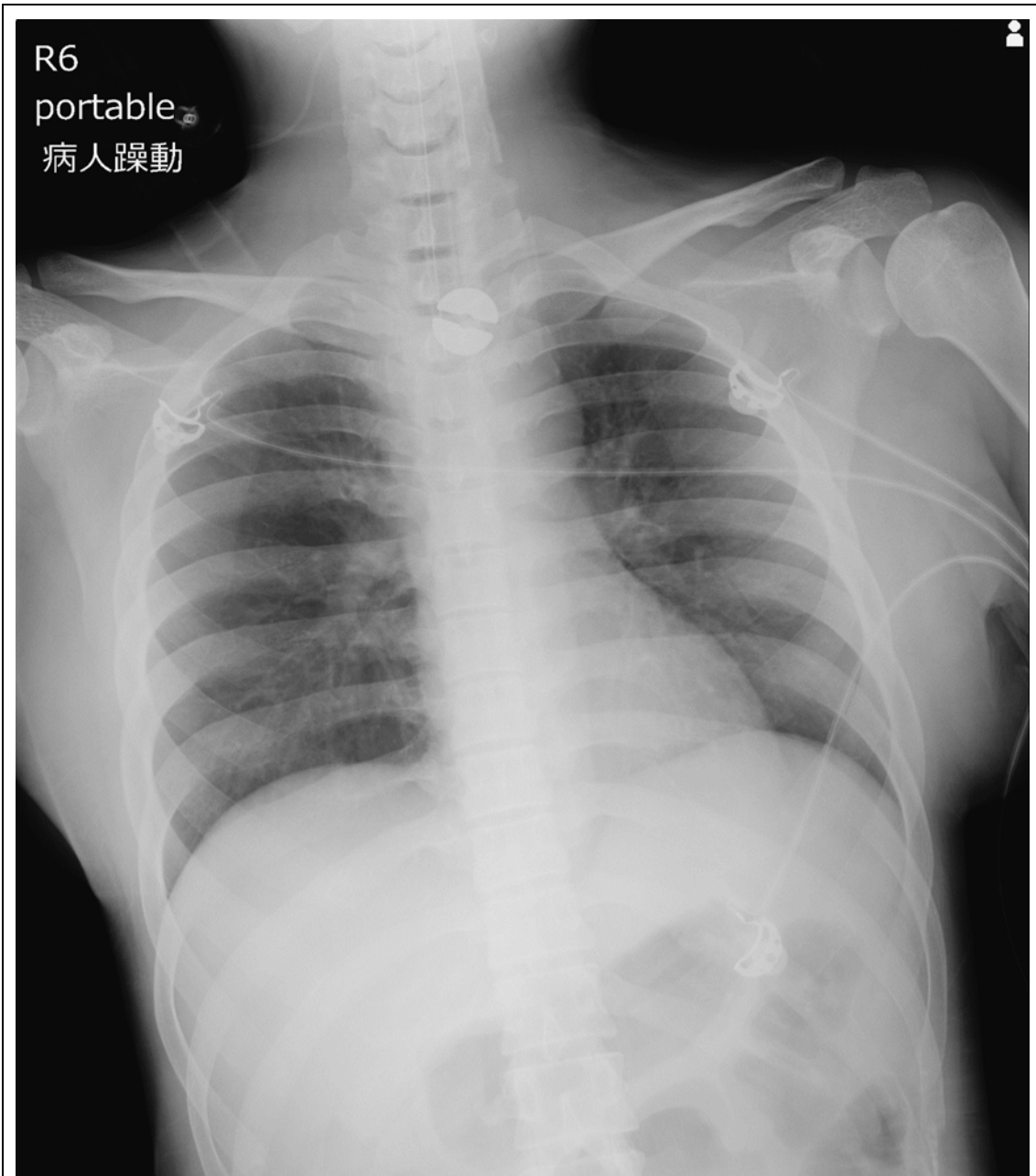


Figure 1. Patient's first chest X ray

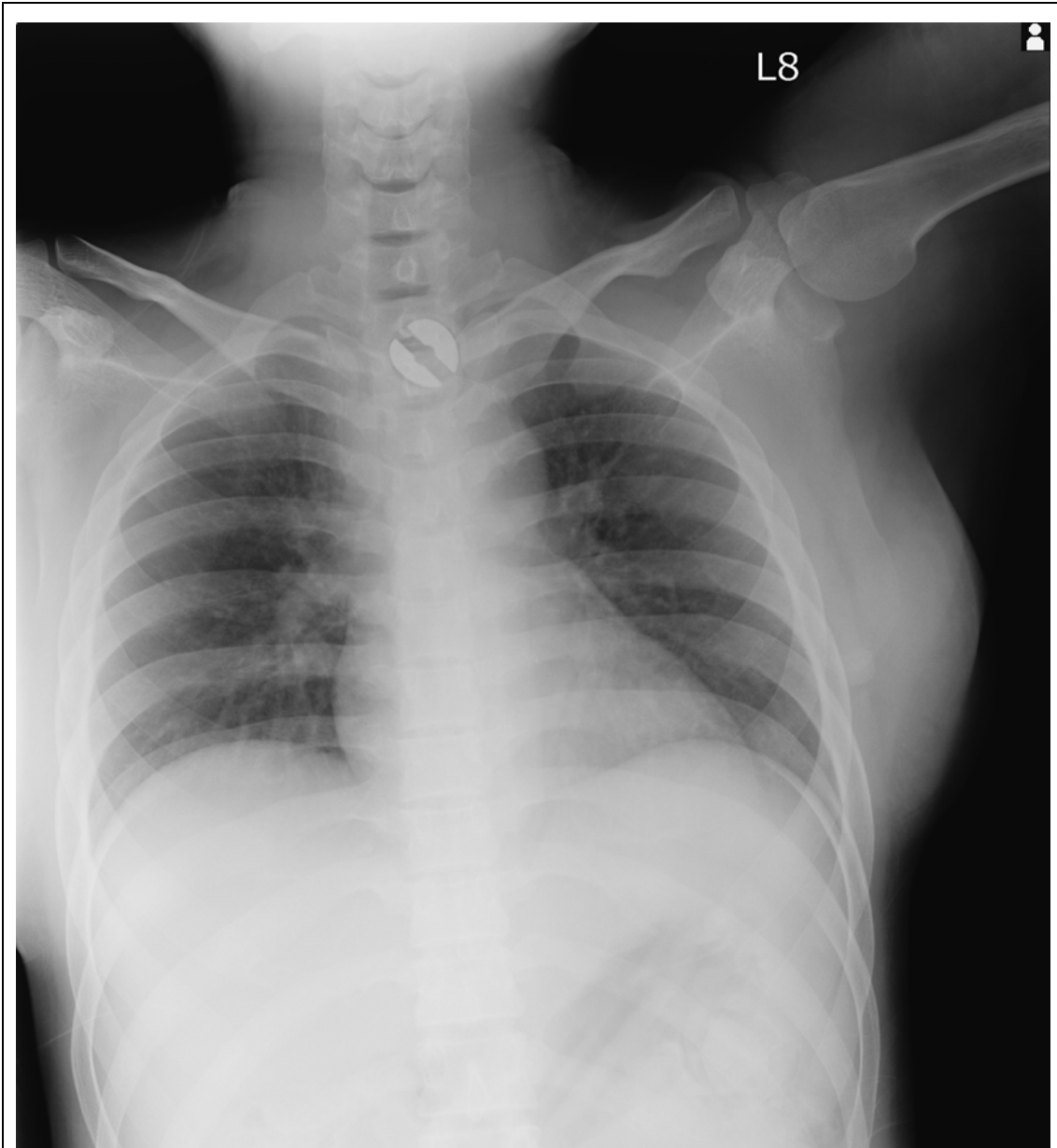


Figure 2. Chest x ray seven days ago

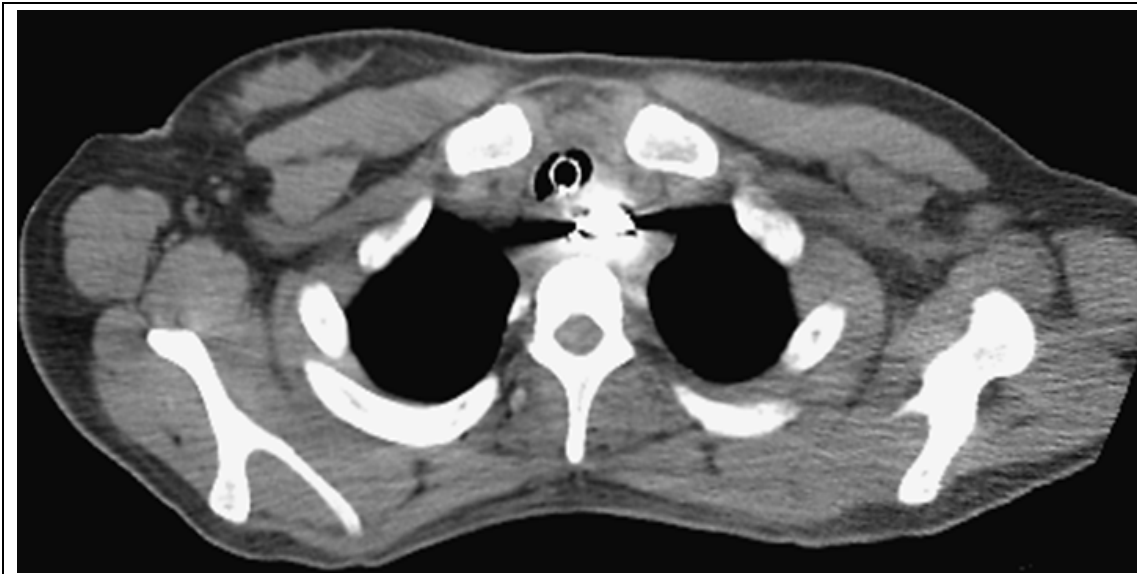

Figure 3. Radiopaque foreign body was found in esophagus



Figure 4. Foreign body was removed from esophagus by surgery.