

中文題目：乳癌病患因化療藥物(Anthracycline)造成的心臟毒性之早期偵測 - 從臨床到實驗室

英文題目：The different distribution of myocardial deformation in Anthracycline induced cardiotoxicity in patients with breast cancer—from bedside to bench

作者：黃聖中¹, 張瑋婷^{1,2}, 馮盈勳³, 郭雨萱³, 陳威宇³, 吳鴻昌³, 黃健泰³, 黃子玲¹, 陳志成^{1,4}

服務單位：¹奇美醫院心臟科²南台科技大學生物技術系³奇美醫院腫瘤科
⁴嘉南藥理大學藥劑部

Abstract

Aims: Anthracycline including Epirubicin and Doxorubicin may induce myocardial dysfunction and lead to poor prognosis. Early detection of minor LV myocardial dysfunction is important for prevention of subsequent cardiotoxicity. Using layer specific speckle tracking echocardiography (STE), we aimed to investigate the progressive distribution of myocardial dysfunction in both clinical and animal perspectives.

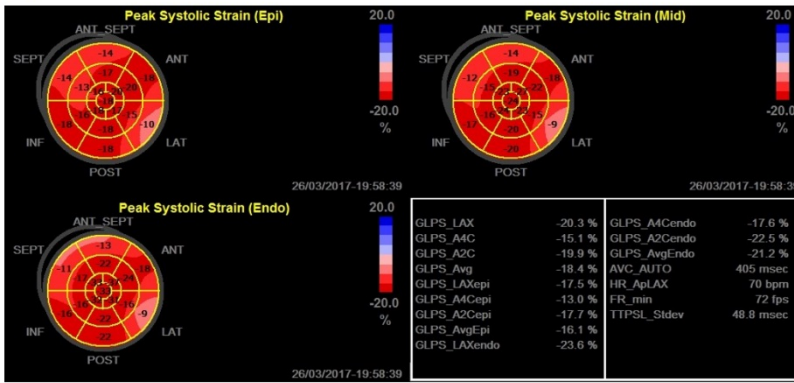
Methods: 125 patients with preserved LV ejection fraction (LVEF) preparing for Epirubicin were recruited. Layer specific STE, including LV longitudinal strain of sub-epicardium (LVLSepi) and sub-endocardium (LVLSendo), were obtained sequentially at baseline, post the first cycle, three cycles and six months of Epirubicin therapy. Also, ten age-, gender-, and LVEF-matched normal volunteers were studied for comparisons. At six months, a decline of LVEF above 10% to <55% was defined as cardiotoxicity. Likewise, the strain was measured in Doxorubicin treated rats and the distribution of myocardial fibrosis was detected eventually.

Results: Post three cycles of therapy, despite no significant changes of conventional LV systolic and diastolic parameters, LVLSendo and LVCSendo in Epirubicin treated group significantly decreased. Compared with conventional echocardiographic parameters, LVLSendo and LVCSendo represented significant impact in predicting the development of cardiotoxicity. Notably, the decline of LVLSendo and LVCSendo were also observed in Doxorubicin treated rats at the early stage. This finding also corresponded to the significant fibrosis at the sub-endocardial layer.

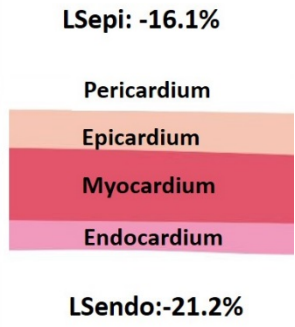
Conclusions: LVLSendo and LVCSendo were found useful for early detection of minor cardiac dysfunction post chemotherapy. It is therefore implied the significance of endocardial involvement in the development of cardiotoxicity.

Key words: Epirubicin induced cardiotoxicity, sub-endocardium, strain, breast cancer

A



B



C

