

中文題目：腎臟到腰大肌竇管 - 一個罕見的泌尿道感染臨床表現

英文題目：Kidney to psoas muscle fistula - An Unusual Presentation of urinary tract infection: A Case Report and Literature Review

作者：高傳紘，陳昭宏，賴寶民

服務單位：台南新樓醫院內科

## **Introduction**

Renal calculus could cause chronic inflammation and serious medical complications. Here we presented a case of kidney to psoas muscle fistula due to obstructive uropathy.

## **Case report**

The 78 year-old gentleman had past history of DM. He suffered from acute consciousness change, hypotension and dyspnea. He was sent to our ER and was admitted to our ICU under the impression of urinary tract infection with septic shock. Due to highly suspect complicated UTI, we arranged abdominal CT to rule out obstructive uropathy. CT showed left psoas muscle abscess, bilateral renal stone (figure 1). We arranged CT-guided abscess drainage with pigtail. His blood culture and abscess culture both showed *E. coli*. Initially pus was drained through pigtail. However, the pigtail drained out clear urine later. We reviewed his CT and kidney to psoas muscle fistula was favored (figure 2).

## **Discussion**

Renal stone would cause obstructive uropathy, chronic inflammation and recurrent UTI. Due to chronic inflammation, fistulas to other organ, such as lung, skin, and colon were reported. In our case, we found a fistula from left kidney to psoas muscle. After pigtail insertion to psoas muscle, pus and then urine was drained out. Finally, the patient expired due to severe sepsis and septic shock.

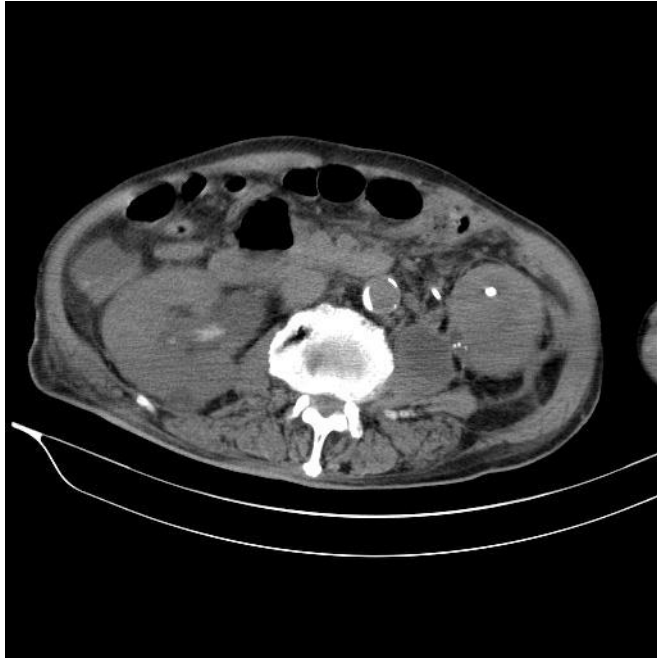


Figure 1: Bilateral renal stone with right hydronephrosis and left D-J. Left psoas muscle abscess formation. A left kidney to psoas muscle fistula was noted.

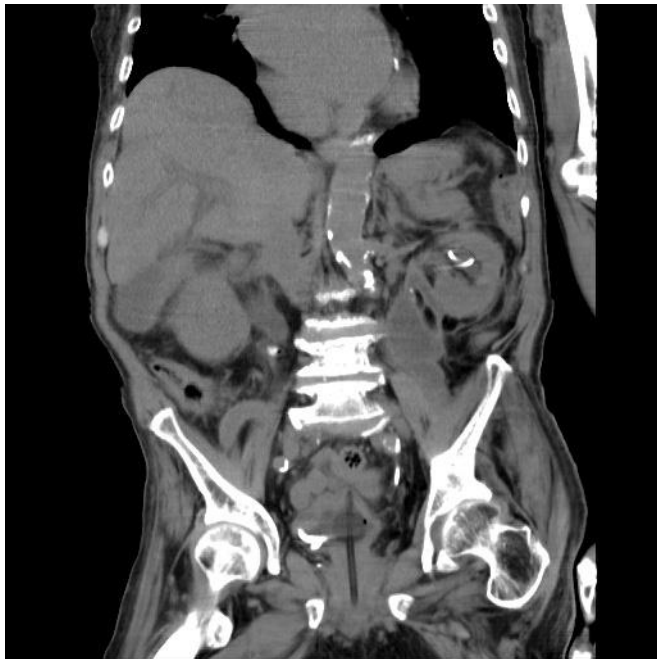

Figure 2: A left kidney to psoas muscle fistula was noted.