

中文題目：TAFRO 症候群: 更具侵略性的 Castleman 氏病亞型

英文題目：More Aggressive and Life-threatening Than Castleman Disease: TAFRO syndrome

作者：林昱廷<sup>1</sup>, 陳嘉峯<sup>2</sup>

服務單位：<sup>1</sup>高雄長庚紀念醫院內科部, <sup>2</sup>高雄長庚紀念醫院風濕免疫科

## Introduction

Castleman disease (CD), an uncommon cluster of heterogeneous lymphoproliferative disorders, is characterized by lymph node enlargement over localized (Unicentric) or generalized (multicentric) regions. The unicentric CD is curable by complete surgical resection, while multicentric CD (MCD) is associated with multiple organs involvement, needing systemic immunotherapy. According to the clinical manifestations, MCD is categorized as idiopathic MCD (iMCD), human herpesvirus 8-associated MCD (HHV8-MCD), and polyneuropathy, organomegaly, endocrinopathy, monoclonal plasma cell disorder, skin changes-associated MCD (POEMS-MCD). In this case report, we described a case of TAFRO syndrome, a newly recognized and life-threatening variant of iMCD, presenting thrombocytopenia, anasarca (generalized edema), fever, and organomegaly.

## Case presentation

A 38-year-old man suffered from intermittent fever for ten days before admission to the infection ward. Initial fever survey, including chest X-ray, abdominal echo and cardiac echo, did not demonstrate specific infection focus. The hemogram revealed normal white count (10,500/ $\mu$ L), and hemoglobin (12.5 g/dL), but thrombocytopenia (41,000/ $\mu$ L) was noted. Other lab tests showed hyperbilirubinemia (total, 1.7mg/dL) and elevated CRP level. Under the impression of atypical infection, doxycycline and ceftriaxone were prescribed empirically at initiation, then escalated to meropenem and levofloxacin due to persistent fever. The repeated culture survey (blood, urine and sputum) did not yield bacteria. Due to progressive onset of bilateral lower leg edema, computed tomography angiography was arranged for possible thromboembolism event, but it revealed diffuse lymph nodes proliferation over bilateral neck, supraclavicular, bilateral axillary, bilateral perihilar, bilateral mediastinal and retroperitoneal regions.

Excisional lymph node biopsy of the left inguinal region was performed, demonstrating atrophic germinal centers surrounded by mantle zones, which are thickened with lymphocytes arranged in layers, shaping the onion-skin appearance (Figure 1), along with extensive vascular proliferation with perivascular hyalinization (Figure 2). Bone marrow survey displayed megakaryocytic hyperplasia, and Hodgkin-like cells were absent. Serology survey of human herpesvirus 8 (HHV8), Epstein-Barr virus (EBV), and autoimmune tests, including ANA, anti-ENA and ANCA, were all negative findings. Due to the presence of plasma cell infiltration and hyaline vascular by pathologic finding, and negative results of bone marrow examination, virus, and autoimmunity survey, Castleman disease, mixed type, was impressed, and we started treatment with methylprednisolone 160mg per day and cyclosporin 300 mg per day.

However, the fever did not subside, along with the progression of lower limb edema to the trunk and ascites formation (anasarca). Abdominal ultrasound revealed hepatomegaly and splenomegaly. Lab data showed thrombocytopenia. Due to the above presentations and deteriorated disease status

refractory to the steroid, iMCD with TAFRO syndrome was highly suspected, and we changed therapy to tocilizumab, a humanized monoclonal antibody against interleukin 6 receptor. There was no complete remission of anasarca after the first dose, then we started a second course, along with cyclophosphamide, etoposide, vincristine, prednisone (CVOP). Followed CT scan at three months later revealed regression of lymph nodes. The thrombocyte counts elevated from 20,000 to 40,000 / $\mu$ L without bleeding signs, then we maintained with low dose steroids.

## **Discussion**

TAFRO syndrome is a life-threatening clinical subtype of iMCD. The term was proposed firstly in 2012 at the Fukushima and Nagoya meetings. The diagnosis of iMCD-TAFRO required confirmation of all three major criteria and at least two of four minor criteria. The major criteria include thrombocytopenia ( $<100,000/\text{mL}$ ), anasarca (pleural effusions and ascites on CT) and systemic inflammation (fever of unknown etiology  $> 37.5^{\circ}\text{C}$  or serum C-reactive protein  $\geq 2$  mg/dL). The minor criteria include Castleman disease-like features on lymph node biopsy, reticulin myelofibrosis, organomegaly (such as hepatomegaly, splenomegaly and lymphadenopathy) and progressive renal insufficiency. Accurate diagnosis of TAFRO syndrome is important for two major reasons. First, the clinical course is more aggressive in TAFRO iMCD, presenting as severe thrombocytopenia and anasarca. A systematic review shows the 2-year survival rate is non-significantly lower in the TAFRO iMCD than those without TAFRO (85% vs 92%,  $p = 0.16$ ). Second, TAFRO iMCD has a more inadequate response to steroid than non-TAFRO iMCD. TAFRO syndrome is regarded as the new subtype of MCD, and the appropriate therapies are still controversial. In our case, the patient meets all major criteria including severe thrombocytopenia ( $<100,000/\text{mL}$ ), anasarca (ascites on CT), fever of unknown etiology ( $>38^{\circ}\text{C}$ ) and three minor criteria, including Castleman disease-like features on lymph node biopsy, reticulin myelofibrosis and organomegaly.

## **Conclusion**

TAFRO syndrome is rare and might be ignored in the clinical setting, and the current treatment strategy is insufficient for disease control. The diagnostic criteria and new optimal therapy need to be established and validated.

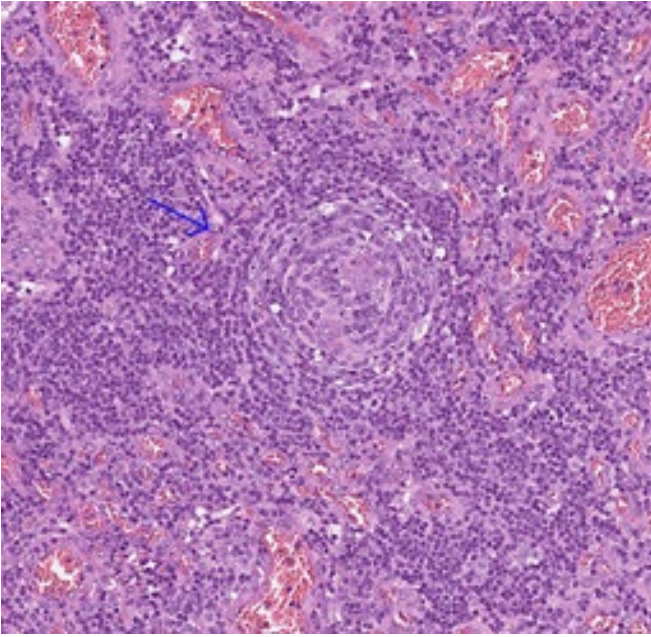


Figure 1  
Atrophic germinal centers and Onion-skin appearance

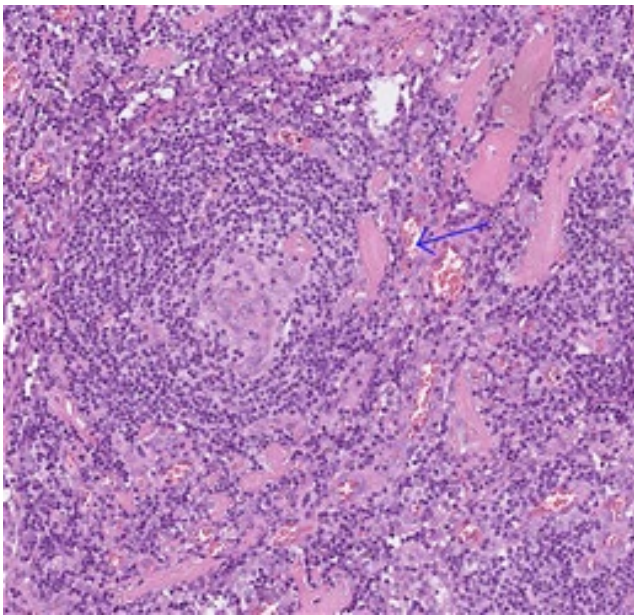


Figure 2  
Extensive vascular proliferation with perivascular hyalinization

#### References

1. Dispenzieri A, Fajgenbaum DC. Overview of Castleman disease. *Blood*. 2020;135:1353–64
2. Tieying Hou, TAFRO syndrome: A case report and review of the literature, *Int J Hematol Oncol Stem Cell Res*. 2018 Oct 1;12(4):253-259.
3. Kah-Lok Chan, Update and new approaches in the treatment of Castleman disease, *J Blood Med*. 2016 Aug 3;7:145-58.