

中文題目：十二指腸鈎蟲感染引起慢性失血導致貧血: 病例報告

英文題目：Anemia due to chronic blood loss by *Ancylostoma duodenale* infection: a case report

作者：葉子瑄¹, 甘偉志^{1,2}

服務單位：¹奇美醫院內科部, ²奇美醫院腎臟內科

Introduction:

Hookworm infections are common in the tropics and subtropics; however, the prevalence of hookworm infection in Taiwan is very low currently due to well-achieved hygiene education and epidemic disease prevention and control. There are two major species of hookworm that cause human infection: *Ancylostoma duodenale* and *Necator americanus*. The route of infection is by direct contact of the skin with contaminated soil or fecal-oral route. Most infected patients remain asymptomatic and iron deficiency anemia due to chronic losses through the digestive tract. Herein, we presented an uncommon-seen case of severe anemia caused by *Ancylostoma duodenale* infection in Taiwan nowadays. In this case, *Ancylostoma duodenale* infection was diagnosed by endoscopy. After anthelmintic treatment, anemia improving markedly.

Case Presentation:

A 74-year-old man with chronic obstructive pulmonary disease, coronary artery disease, atrial fibrillation, old cerebrovascular accident, and hypertension presented with progressive dyspnea for days. Accompanied with some tarry stool during emergency department. Brief physical examination revealed irregular heartbeats, bilateral wheezing breath sound, soft abdomen, warm extremities. Differential diagnoses included acute exacerbations of chronic obstructive pulmonary disease, anemia caused by upper gastrointestinal bleeding, pneumonia. Laboratory tests revealed hemoglobin of 4.7 g/dL, hematocrit 17.5 %, leukocytes $5.9 \times 10^3/\mu\text{L}$ (eosinophils 5.8 %), platelets $251 \times 10^3/\mu\text{L}$, creatinine 0.77 mg/dL, and coagulation profile within normal ranges. Chest radiograph illustrated no obvious pneumonia patch. Furthermore, the upper endoscopy had been arranged under the impression of upper gastrointestinal bleeding, and it showed multiple hookworms at duodenum adhered to the mucosa (Figure 1-4). Pathologic report showed consistence with *Ancylostoma duodenale*. Nevertheless, fecal examination by Lumbreras rapid sedimentation showed no hookworm eggs. The patient was treated with Mebendazole 100mg BID for three days. After treatment, anemia improving markedly with hemoglobin of 10.3 g/dL after one month and following fecal examination by merthiolate iodine formaldehyde still revealed no hookworm eggs.

Discussion:

Hookworm infections is very uncommon in Taiwan nowadays. Clinical manifestations of hookworm infections include dermal penetration by infecting larvae, transpulmonary passage, acute

gastrointestinal symptoms, and chronic nutritional impairment. Hookworms may cause blood loss by lacerating capillaries and production of anticoagulant peptides that inhibit activated factor X and factor VIIa and inhibit platelet activation. The daily losses of blood, iron, and albumin can lead to anemia and contribute to impaired nutrition, especially in patients with heavy infection. Preventive measures consist of drinking safe water, properly cleaning and cooking food, hand washing, and wearing shoes. Anthelmintic drugs may be administered to populations at risk and diagnosed. Eosinophilia has been attributed to persistent attachment of adult worms to the intestinal mucosa. Thus, unexplained eosinophilia may be a major clue to the presence of a parasitic infection.

Conclusion:

The prevalence of hookworm infections is very low in Taiwan for a long time due to good hygiene measures. It would lead to anemia and contribute to impaired nutrition. Moreover, unexplained eosinophilia may be a major clue to the presence of a parasitic infection.

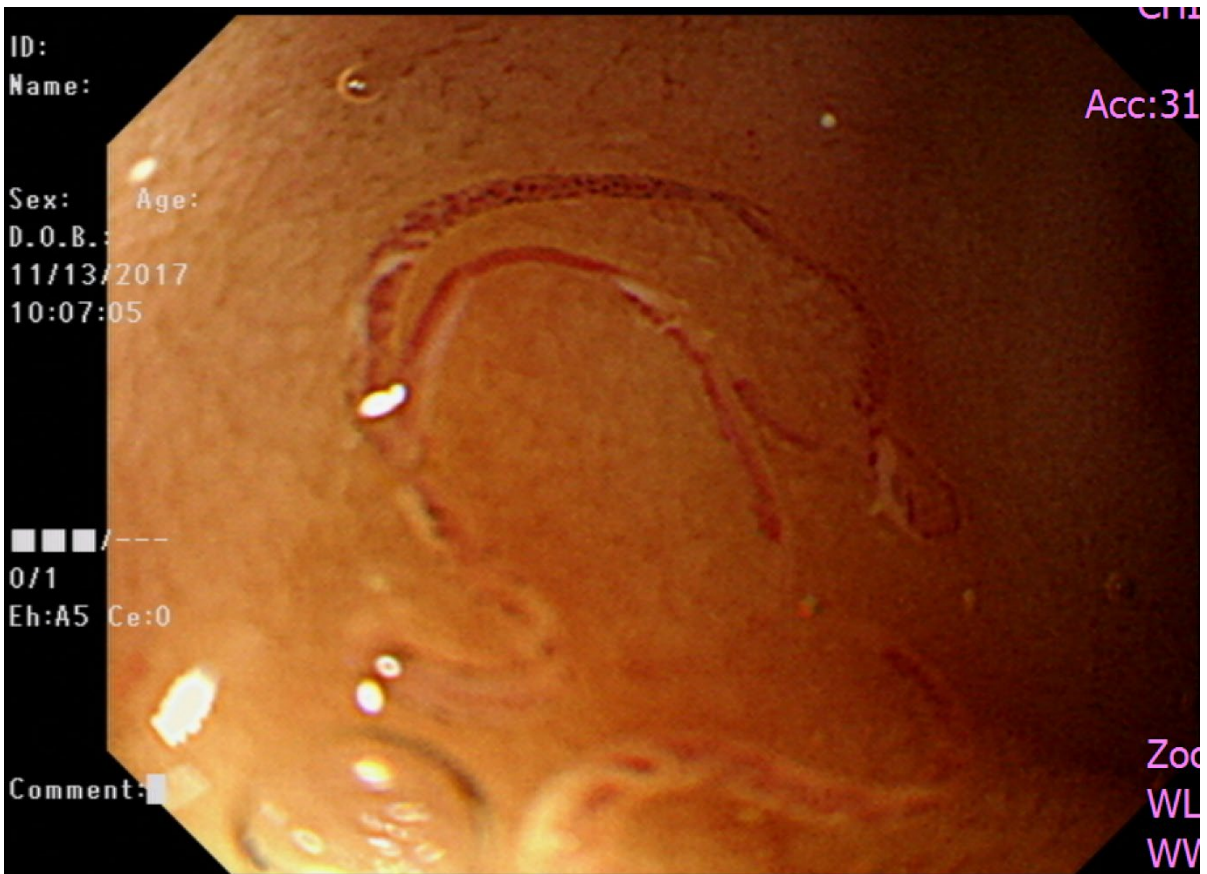

Figure 1.

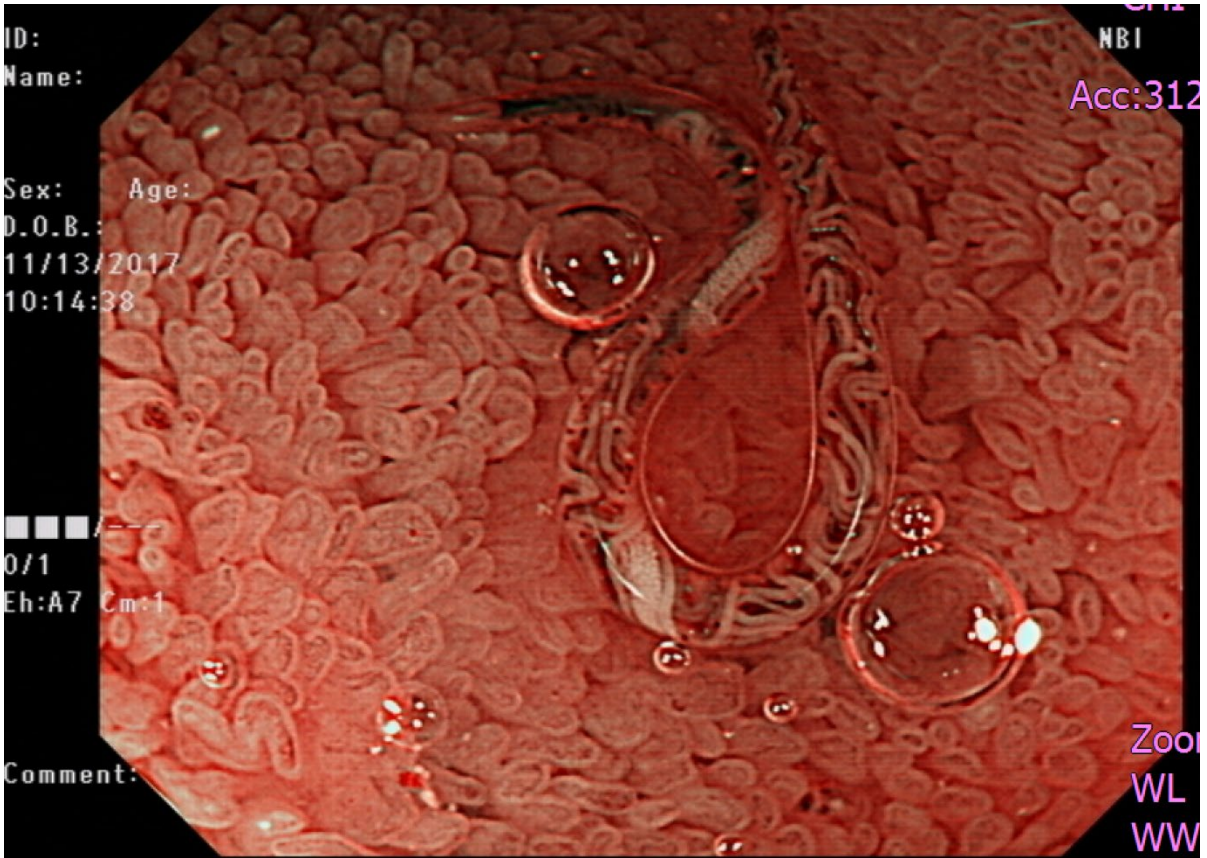


Figure 2.

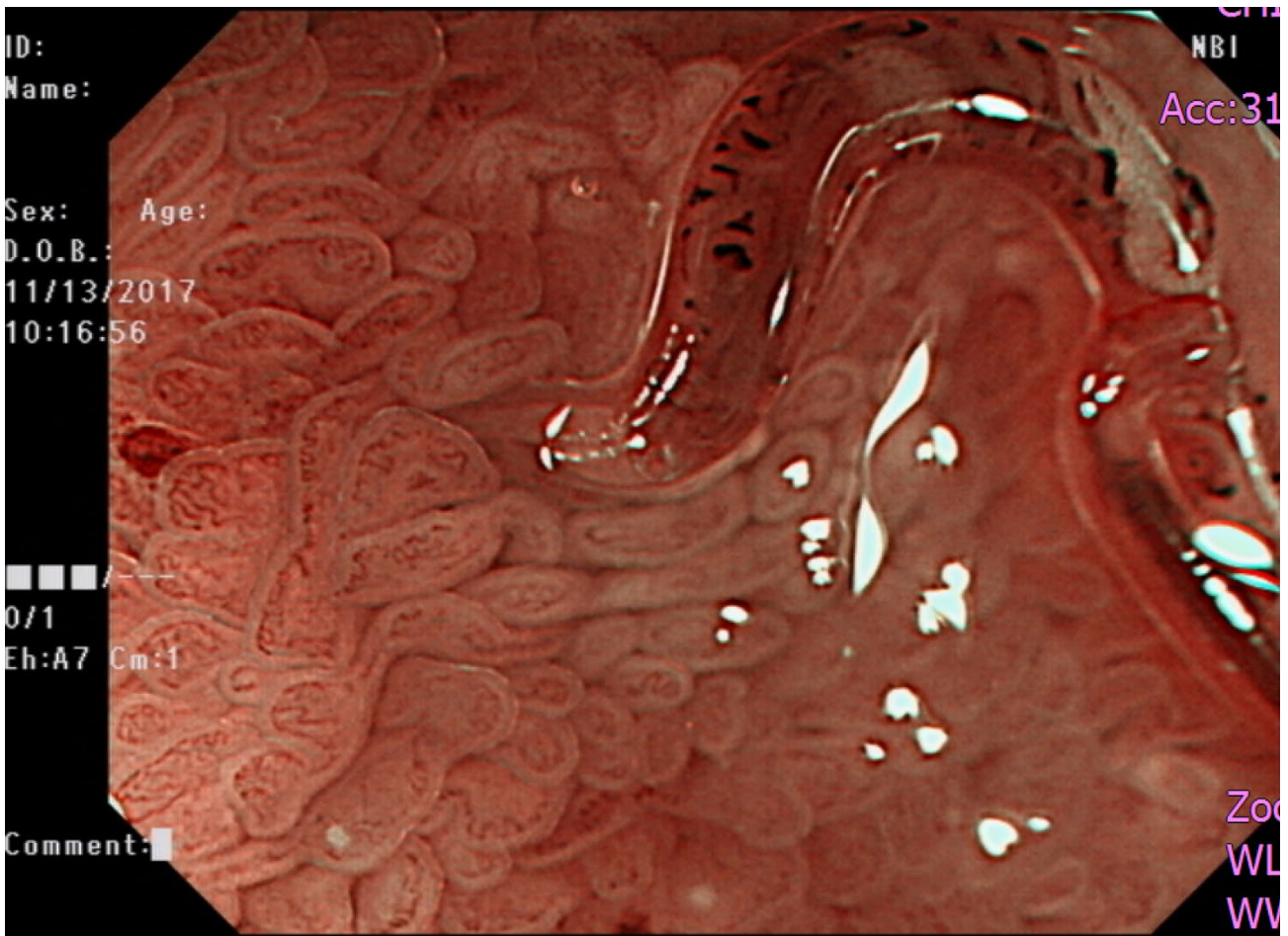


Figure 3.



Figure 4.