

中文題目：脈衝式治療於類固醇抗性免疫性腦炎的應用

英文題目：Pulse corticosteroid therapy in the treatment of steroid-refractory immune checkpoint inhibitors related encephalitis

作者：賴冠璋<sup>1</sup>，陳三奇<sup>2</sup>

服務單位：臺北榮民總醫院內科部<sup>1</sup>；臺北榮民總醫院腫瘤醫學部<sup>2</sup>

## Introduction

In the past years, immune checkpoint inhibitors (ICIs) have been approved for the treatment of many types of cancers. Despite ICIs demonstrated the promising therapeutic benefits, inflammatory side effects termed immune-related adverse events (irAEs) may develop. Among all the irAEs, neurological toxicities that varied from peripheral neuropathy to disorders of central nervous system are rare but can be fatal. When combined with anti-cytotoxic T-lymphocyte-associated-4 (anti-CTLA4) and anti-programmed cell death receptor 1 (anti-PD-1), the incidence is higher. Regarding ICI-related encephalitis, it is a serious neurologic complication that needs to be early identified and managed. According to the current guideline, ICIs should be withheld in all-grade of ICI-related encephalitis. Methylprednisolone 1 to 2 mg/kg is recommended as a mainstay treatment strategy. The patients who develop severe or progressing neurological symptoms should be treated with pulse corticosteroid therapy (parenteral methylprednisolone 1 g for days) with or without intravenous immunoglobulin (2 g per kilograms for days), rituximab or plasmapheresis. Here, we reported a case of steroid-refractory ICI-related encephalitis who were successfully treated with pulse corticosteroid therapy.

## Case presentation

A 55-year-old male with medical history carrier of chronic hepatitis B virus and essential hypertension. He had never taken illicit drugs nor drank alcohol. He was diagnosed with early-stage hepatocellular carcinoma (HCC) and then underwent resection in 2019. However, he got dysmetria, headache, and unsteady gait in March 2022 which was diagnosed as a left parietooccipital brain tumor with hemorrhage change. Craniotomy with brain tumor removal was performed, and the surgical pathology confirmed metastatic HCC. Besides, computed tomography (CT) scan showed liver recurrence and lung metastasis. Due to the advanced HCC, he received first-line systemic therapy with atezolizumab and bevacizumab every three weeks since May 30th, 2022. However, one week after cycle 2, progressive disturbance of consciousness, generalized weakness, nausea, and vomiting were noticed. He was sent to our hospital. On examination, the patient had agitated mood and answered questions inappropriately. He was disoriented to person, time, and place. The neurologic examination revealed that the Glasgow Coma Scale E4V2M4, and negative results of Kerning's or Brudzinski's sign. The laboratory data showed a white blood count 11,190 /ul, alanine aminotransferase 83 mg/dl, serum creatinine 0.58 mg/dl, CRP 14.83 mg/dl, and procalcitonin 0.35 ng/ml. The brain CT scan disclosed no visible tumor. The cerebrospinal fluid (CSF) analysis showed WBC count 21/microL, with lymphocyte 65%, CSF protein concentration 33 mg/dl and CSF glucose concentration 78 mg/dL. Empirical antibiotics with vancomycin and ceftriaxone were given for the possible of meningitis. Thereafter, the polymerase chain reaction of CSF showed no evidence of bacterial or viral infection and the cytology showed negative result. The thyroid function test showed free tetraiodothyronine

(free T4) was 7.77 ng/dl and thyrotropin (TSH) below 0.005 uIU/ml which suggested ICI-related hyperthyroidism. The electroencephalography (EEG) demonstrated diffuse slowing without epileptiform activity (**Figure 1A**). In summary, the impressions were grade 4 ICI-related encephalitis and grade 3 ICI-related overt thyrotoxicosis. Intravenous dexamethasone (0.5 mg/kg/day) and propylthiouracil (PTU) 400mg daily were initially prescribed. However, his symptoms were only partially improved and he still presented with slow movement and thinking. Therefore, pulse corticosteroid therapy with methylprednisolone 1g for three days was administered. The brain magnetic resonance imaging (MRI) examination after pulse corticosteroid therapy disclosed no remarkable encephalitis and no residual or recurrent brain metastasis (**Figure 1B**). Five days after pulse corticosteroid treatment, the patient recovered from cognitive impairment and coordination dysfunction. We tapered down steroid and PTU dosage gradually and he was discharged with stable medical conditions.

## Discussion

ICI-related encephalitis is a rare toxicity and the incidence is less than 1% in all irAE.<sup>1,2</sup> The diagnosis of ICI-related encephalitis remains a great challenge for physician. It is a diagnosis of exclusion. Metabolic encephalopathy, septic encephalopathy, CNS infection, brain metastasis, paraneoplastic syndrome or leptomeningeal carcinomatosis should be considered in the differential diagnosis.<sup>3,4</sup> If it is feasible, CSF analysis should be performed. The antineuronal antibodies, including anti-Ma2 antibodies, anti-N-methyl-D-aspartate receptor antibodies, anti-Hu antibodies and anti-contactin-associated protein 2 antibodies, and anti-glutamate decarboxylase-65 antibodies can be detected from CSF samples in some patients.<sup>3-6</sup> Electroencephalogram (EEG) may demonstrate epileptiform abnormalities or non-epileptiform activities, such as diffuse slowing.<sup>5,7,8</sup> However, there is no specific pattern of EEG for the diagnosis of ICI-related encephalitis. The brain MRI image may show non-specific abnormality and negative findings sometimes.<sup>4,6</sup> A systemic review of 82 cases with ICI-related encephalitis showed patients without MRI finding had better outcomes in comparison to those with abnormal MRI image.<sup>8</sup> The treatment of ICI-related encephalitis is established based on the management of autoimmune encephalitis or expert's opinions.<sup>8,9</sup> According to current guidelines, high-dose corticosteroid was recommended for the front-line treatment. For patients developed steroid-refractory encephalitis, pulse corticosteroid with methylprednisolone 1 g/day for few days with or without intravenous immunoglobulin (IVIG), or plasmapheresis were strongly recommended. A case series with 11 cases of ICI-related encephalitis described 90% neurological improvement by using pulse corticosteroid therapy.<sup>10</sup>

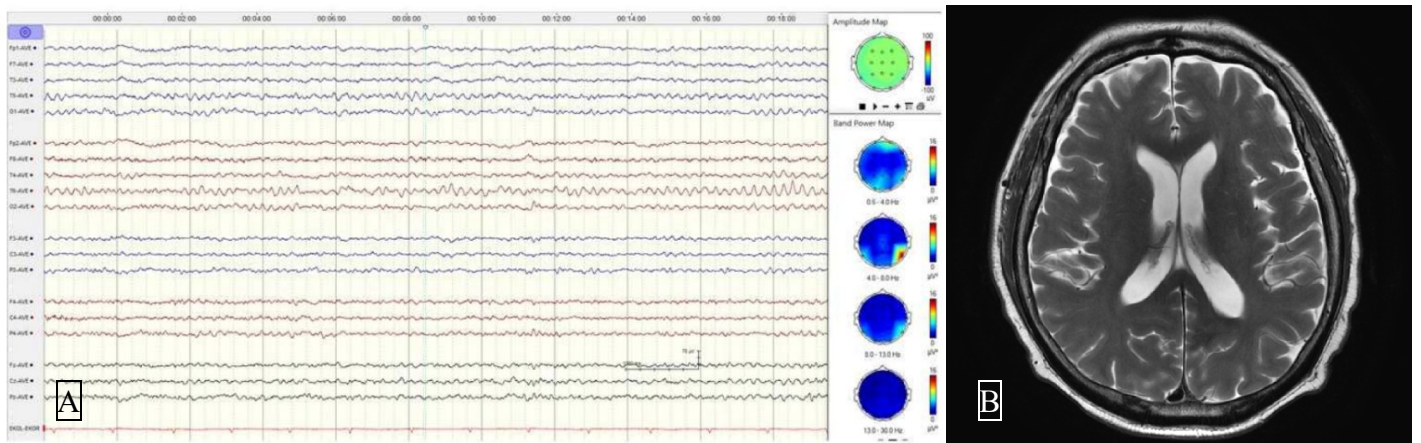
In this case, the clinical presentation and the findings of CSF, brain MRI, and EEG suggested the diagnosis of ICI-related encephalitis. Because of the steroid-refractory meningitis, pulse corticosteroid therapy was given. After one month of follow-up, this patient completely recovered from encephalitis without any neurological sequelae. However, atezolizumab was discontinued and his treatment was shifted to other anti-cancer drugs.

## Conclusion

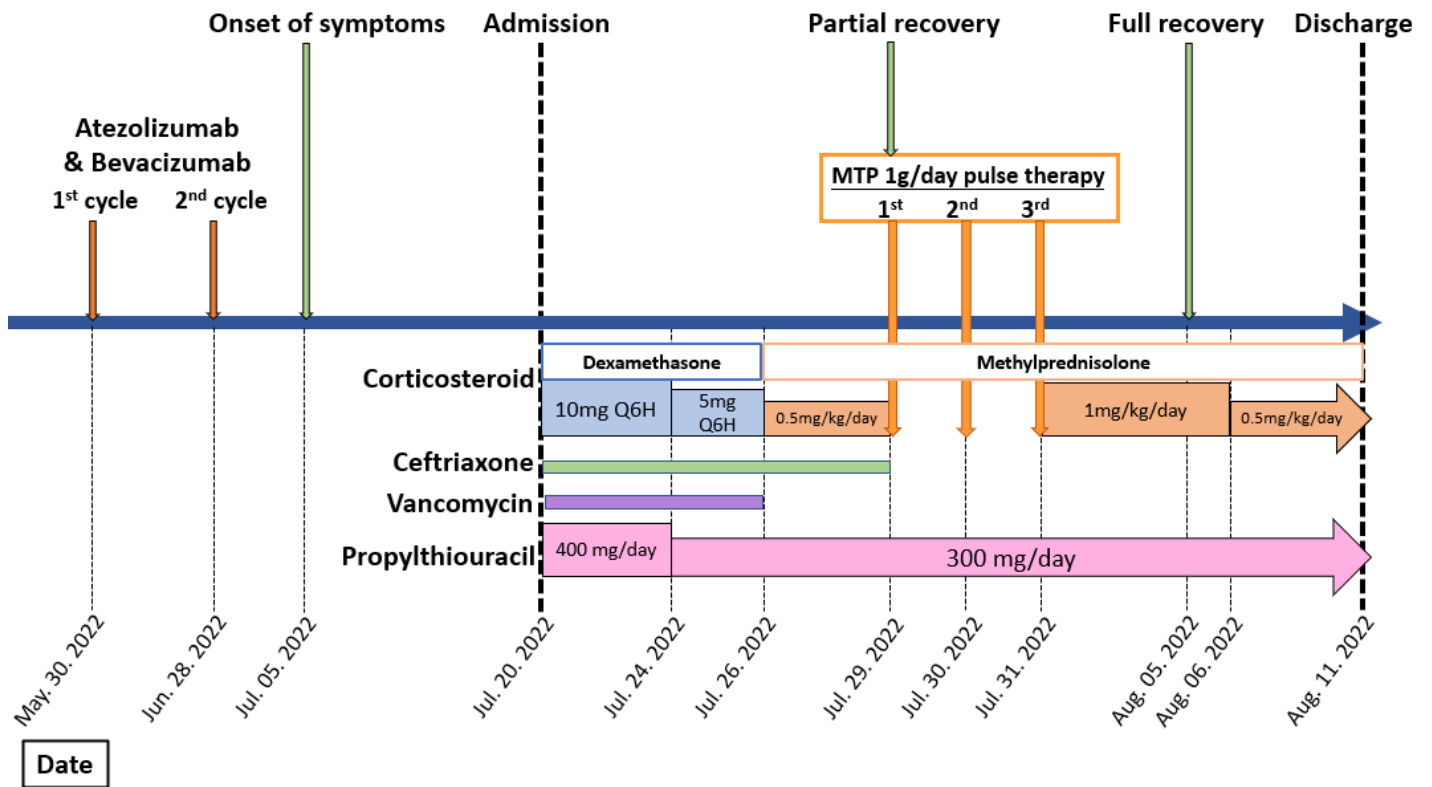
The ICI-related encephalitis is uncommon but life-threatening. The neurologic dysfunction may deteriorate rapidly which was required early identification and intervention. Pulse corticosteroid therapy is an effective

treatment for steroid-refractory encephalitis. Given the lack of strong evidence, more data are needed to support role of pulse corticosteroid therapy for ICI-related encephalitis.

**Figure 1.** The electroencephalography and brain image of the patient. (A) EEG showed diffuse background slowing with frequency at 7-8 Hz. (B) Axial T2-weighted MRI shows nearly total regression of previous tiny enhancing foci in bilateral cerebrum



**Figure 2.** Timeline of the patient's clinical course including clinical events, medication, and drug dosage



## References

1. Larkin J, Chmielowski B, Lao CD, et al. Neurologic Serious Adverse Events Associated with Nivolumab Plus Ipilimumab or Nivolumab Alone in Advanced Melanoma, Including a Case Series of Encephalitis. *Oncologist* 2017; **22**(6): 709-18.
2. Shah S, Dunn-Pirio A, Luedke M, Morgenlander J, Skeen M, Eckstein C. Nivolumab-Induced Autoimmune Encephalitis in Two Patients with Lung Adenocarcinoma. *Case Rep Neurol Med* 2018; **2018**: 2548528.
3. Fan S, Ren H, Zhao L, et al. Neurological immune-related adverse events associated with immune checkpoint inhibitors: A review of the literature. *Asia Pac J Clin Oncol* 2020; **16**(6): 291-8.
4. Martins F, Sofiya L, Sykiotis GP, et al. Adverse effects of immune-checkpoint inhibitors: epidemiology, management and surveillance. *Nat Rev Clin Oncol* 2019; **16**(9): 563-80.
5. Albarran V, Chamorro J, Rosero DI, et al. Neurologic Toxicity of Immune Checkpoint Inhibitors: A Review of Literature. *Front Pharmacol* 2022; **13**: 774170.
6. Suzuki S. Encephalitis as an immune-related adverse event. *J Neurol Neurosurg Psychiatry* 2020; **91**(7): 680.
7. Feng S, Coward J, McCaffrey E, Coucher J, Kalokerinos P, O'Byrne K. Pembrolizumab-Induced Encephalopathy: A Review of Neurological Toxicities with Immune Checkpoint Inhibitors. *J Thorac Oncol* 2017; **12**(11): 1626-35.
8. Velasco R, Villagran M, Jove M, et al. Encephalitis Induced by Immune Checkpoint Inhibitors: A Systematic Review. *JAMA Neurol* 2021; **78**(7): 864-73.
9. Haanen J, Carbone F, Robert C, et al. Management of toxicities from immunotherapy: ESMO Clinical Practice Guidelines for diagnosis, treatment and follow-up. *Ann Oncol* 2017; **28**(suppl\_4): iv119-iv42.
10. Taliansky A, Furman O, Gadot M, et al. Immune checkpoint inhibitors-related encephalitis in melanoma and non-melanoma cancer patients: a single center experience. *Support Care Cancer* 2021; **29**(12): 7563-8.