

中文題目：經導管主動脈瓣膜置換術後晚期再發完全房室結傳導阻滯

英文題目：Late re-occurring complete atrioventricular block in a patient receiving transcatheter aortic valve implantation

作者：林孟緯¹，陳儒逸^{1,2}

服務單位：¹成功大學醫學院附設醫院內科部，²成功大學醫學院附設醫院內科部心臟血管科

Abbreviations and Acronyms

AVB = atrioventricular block

ECG = electrocardiography

EPS = electrophysiology study

HFmrEF = heart failure with mildly reduced ejection fraction

ILR = implantable loop recorder

LPFB = left posterior fascicular block

PPI = permanent pacemaker implantation

PPM = permanent pacemaker

RBBB = right bundle branch block

TAVI = transcatheter aortic valve implantation

TVP = temporary transvenous pacing

Introduction:

Bradyarrhythmias requiring PPI remains a common complication in patients receiving TAVI. Although the vast majority of patients developed conduction disturbance directly after TAVI, still some patients showed an initially uneventful course after the procedure and developed significant conduction disturbance very late after the intervention. There are several known factors associated with increased risk of conduction abnormalities following TAVI, optimum timing for permanent pacemaker implantation remained a debating issue, and published reports lacked long-term outcomes. Here we present a case of late re-occurring complete AVB after TAVI with asystole episode detected by ILR during clinical follow up.

Case presentation:

An 88-year-old woman with severe aortic stenosis was admitted for chronic dyspnea. Her medical history included diabetes mellitus, hypertension, hyperlipidemia, chronic kidney disease stage 3, HFmrEF, New York Heart Association (NYHA) IV, RBBB and LPFB (Figure 1A). Following thorough assessment, echocardiography showed heavily calcified aortic valve (0.26 cm²), high mean pressure gradient (62 mmHg) of aortic valve with mildly reduced left ventricular ejection fraction (49.2%). Early aortic valve replacement was strongly recommended because of her worsening condition. Coronary angiography revealed 90% stenosis at middle to distal part of left anterior descending artery and one bare-metal stent was placed. The patient has high surgical risks (Society of Thoracic Surgeons (STS) score: 23.9%), and we suggested her for TAVI.

Computed tomography showed a calcified tri-leaflet aortic valve. The aorta had a normal caliber without evidence of aneurysm, and both iliac arteries were patent without significant calcification or stenosis. Small diameter of sinus Valsalva and short height of coronary orifice were noticed, which was 26.0 mm and 11.9 mm, respectively. Therefore, a relatively deep implantation depth of 26 mm self-expanding valve (CoreValve EvoR; Medtronic) was placed with left main wire protection using a right femoral artery approach to prevent coronary obstruction (Figure 2). TVP was performed via right internal jugular vein and programmed VVI with 60 beat per minute as our routine procedure after TAVI. First day after the procedure, complete AVB (Figure 1B) intermittently appeared, with spontaneous recovery to baseline on the 5th day (Figure 1C). The post-TAVI echocardiography showed improved aortic stenosis condition with mean pressure gradient declined to 11 mmHg. TVP was removed on 14th day after TAVI because prolonged hospitalization for urinary tract infection.

During clinical follow up, ILR (LINQ; Medtronic) was implanted on 20th day after TAVI due to suspicious bradycardia related symptoms and the recordings showed transient complete AVB followed by 15 seconds of asystole (Figure 1D). Therefore, PPM (Advisa™ DR MRI SureScan™; Medtronic) was implanted with left bundle branch area pacing and DDDR mode (Figure 3). After PPI, follow up 12-lead ECG showed sinus rhythm with RBBB and LPFB (Figure 1E).

Discussion:

Our patient has spontaneous recovery from transient complete AVB post TAVI. However, symptomatic bradycardia followed by complete AVB and 15 seconds of asystole were detected by ILR almost one month after TAVI. Distinct P waves with dropped QRS complex and lack of deteriorating sensation on ILR are both evidence of a true asystole episode.¹ Symptomatic complete AVB served as level I indication for PPI.² Moreover, several predictors for PPI after TAVI were identified in our case, such as pre-existing RBBB, prosthesis oversizing, and Medtronic CoreValve.³ Therefore, PPI could be considered in early period of transient complete AVB post TAVI.

Conduction abnormalities are common and severe complications post TAVI. Approximately 7~28% of patients require a PPI.^{4,5} Currently, indications and timing of PPI remain a debating issue, and lack long-term outcomes in current published studies. The current European Society of Cardiology (ESC) guidelines suggested a PPM should be implanted in those with complete or high-grade AVB that persists for 24~48 hours or those with new-onset alternating BBB after TAVI.² However, conduction disturbance may recover and often with unpredictable timing. In our patient, complete AVB spontaneously recovered on the 5th day after TAVI and no conduction disturbance was noted during the rest of post-procedural observation up to two weeks. Thus, whether the decision of PPI should be based on conduction abnormalities noted during 24~48 hours after TAVI remains questionable.

Conduction disturbance may spontaneous recovery due to resolution of the inflammation and edema caused during the TAVI.⁵ The presence of pre-existing RBBB has been established as most consistent predictors of PPI after TAVI.⁶⁻⁹ Mangieri et al.¹⁰ found that pre-existing RBBB and PR interval prolongation after TAVI are predictors for late PPM (≥ 48 h) requirement. Therefore, we suggest in these patients, EPS or outpatient cardiac rhythm monitoring is necessary (Figure 4) even though the conduction disturbance may

recover in 48 hours.

Several studies showed ambulatory ECG monitoring systems are safe, useful and helpful diagnostic tools in TAVI recipients.^{11,12} To our interest, for patients with known predictors associated with high risk of PPI^{3,13}, ILR can be an alternative way for monitoring cardiac rhythm after TAVI and thus decrease hospitalization duration (Figure 4). However, asystole events detected by a ILR may not always be clinically significant. Inappropriate detection such as poor interface-contact¹⁴ or external interference^{15,16} may provoke false asystole alarm.

Conclusion:

Late occurrence of conduction disturbance should be recognized as a significant contributor to postprocedural outcome after TAVI. Outpatient cardiac rhythm monitoring is potentially a safe solution to allow timely recognition of conduction disturbance requiring PPI.

References:

1. Ali H, Sorgente A, Daleffe E, Cappato R. Asystole detected by implantable loop recorders: true or false? *Ann Noninvasive Electrocardiol.* 2014;19(6):595-597.
2. Glikson M, Nielsen JC, Kronborg MB, et al. 2021 ESC Guidelines on cardiac pacing and cardiac resynchronization therapy. *Europace.* 2022;24(1):71-164.
3. Nazif TM, Dizon JM, Hahn RT, et al. Predictors and clinical outcomes of permanent pacemaker implantation after transcatheter aortic valve replacement: the PARTNER (Placement of AoRtic TraNscathetER Valves) trial and registry. *JACC Cardiovasc Interv.* 2015;8(1 Pt A):60-69.
4. Winter MP, Bartko P, Hofer F, et al. Evolution of outcome and complications in TAVR: a meta-analysis of observational and randomized studies. *Sci Rep.* 2020;10(1):15568.
5. Auffret V, Puri R, Urena M, et al. Conduction Disturbances After Transcatheter Aortic Valve Replacement: Current Status and Future Perspectives. *Circulation.* 2017;136(11):1049-1069.
6. Zahid S, Khan MZ, Ullah W, et al. In-hospital outcomes of TAVR patients with a bundle branch block: Insights from the National Inpatient Sample 2011-2018. *Catheter Cardiovasc Interv.* 2022;100(3):424-436.
7. Watanabe Y, Kozuma K, Hioki H, et al. Pre-Existing Right Bundle Branch Block Increases Risk for Death After Transcatheter Aortic Valve Replacement With a Balloon-Expandable Valve. *JACC Cardiovasc Interv.* 2016;9(21):2210-2216.
8. Waksman R, Steinvil A. Pre-Transcatheter Aortic Valve Replacement Right Bundle Branch Block: A Bundle of Trouble. *JACC Cardiovasc Interv.* 2017;10(15):1575-1577.
9. Egger F, Nurnberg M, Rohla M, et al. High-degree atrioventricular block in patients with preexisting bundle branch block or bundle branch block occurring during transcatheter aortic valve implantation. *Heart Rhythm.* 2014;11(12):2176-2182.
10. Mangieri A, Lanzillo G, Bertoldi L, et al. Predictors of Advanced Conduction Disturbances Requiring a Late (\geq 48 H) Permanent Pacemaker Following Transcatheter Aortic Valve

Replacement. *JACC Cardiovasc Interv.* 2018;11(15):1519-1526.

11. Muntane-Carol G, Philippon F, Nault I, et al. Ambulatory Electrocardiogram Monitoring in Patients Undergoing Transcatheter Aortic Valve Replacement: JACC State-of-the-Art Review. *J Am Coll Cardiol.* 2021;77(10):1344-1356.
12. Scotti A, Sturla M, Coisne A, et al. Monitoring conduction disturbances following TAVR: Feasibility study of early discharge using a novel telemetry patch. *Int J Cardiol.* 2022;364:35-37.
13. Sammour Y, Krishnaswamy A, Kumar A, et al. Incidence, Predictors, and Implications of Permanent Pacemaker Requirement After Transcatheter Aortic Valve Replacement. *JACC Cardiovasc Interv.* 2021;14(2):115-134.
14. Bortnik M, Occhetta E, Magnani A, Degiovanni A, Marino P. Inappropriate asystole detection in early postoperative phase after loop recorder implantation. *ISRN Cardiol.* 2011;2011:146062.
15. de Cock CC, Spruijt HJ, van Campen LM, Plu AW, Visser CA. Electromagnetic interference of an implantable loop recorder by commonly encountered electronic devices. *Pacing Clin Electrophysiol.* 2000;23(10 Pt 1):1516-1518.
16. Thaker JP, Patel MB, Jongnarangsin K, Liepa VV, Thakur RK. Electromagnetic interference with pacemakers caused by portable media players. *Heart Rhythm.* 2008;5(4):538-544.

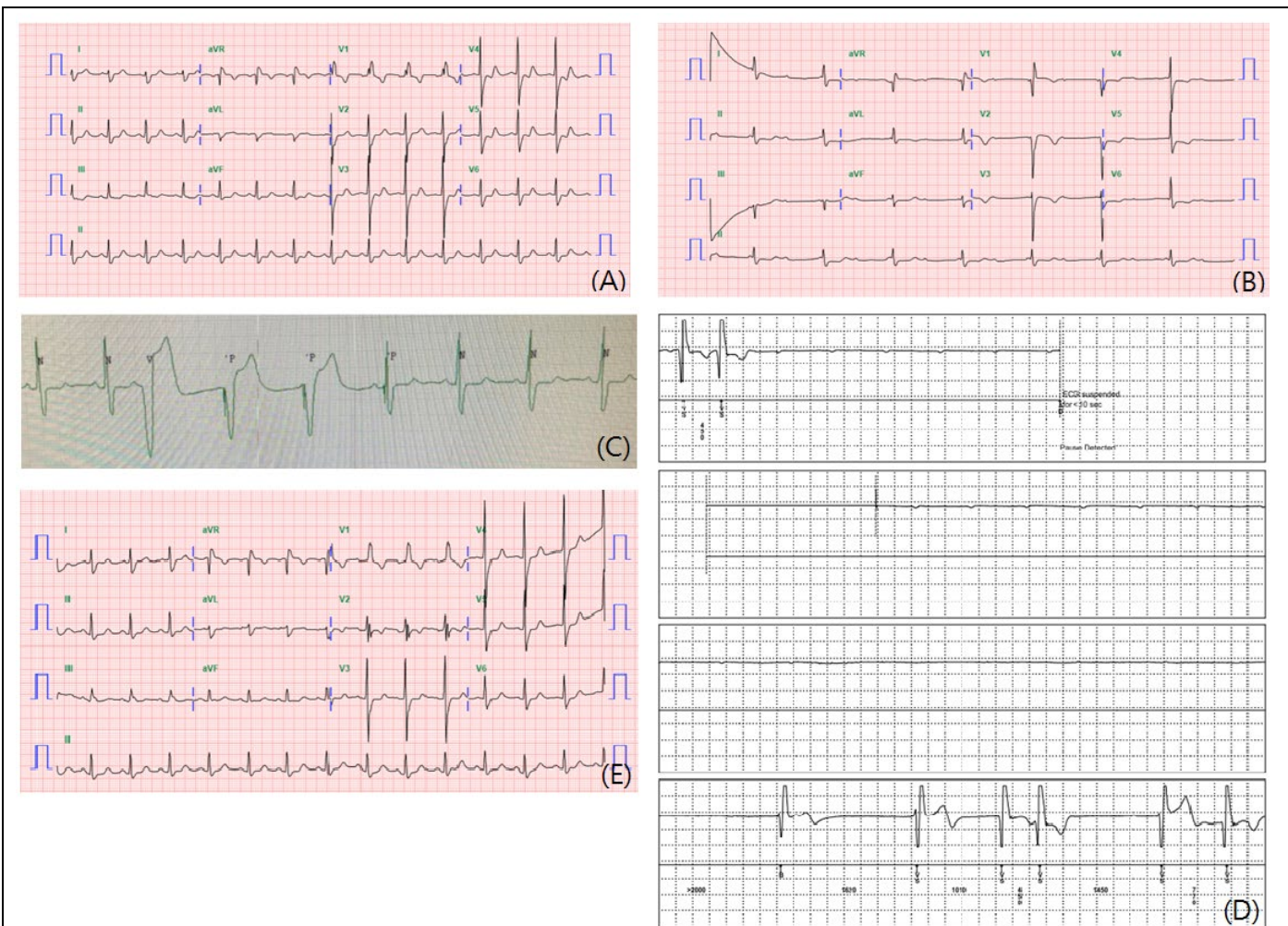


Figure 1. (A) The 12-lead ECG on admission, pre-TAVI, demonstrated sinus rhythm with RBBB and LPFB. (B) Complete AVB was noticed on the next day after TAVI. (C) The rhythm spontaneously recovered to sinus rhythm with RBBB and LPFB on the 5th day after TAVI. (D) Complete AVB with asystole for 15 seconds was recorded by an ILR (LINQ; Medtronic). (E) After PPI, the follow up 12-lead ECG revealed sinus rhythm with RBBB and LPFB as her baseline.

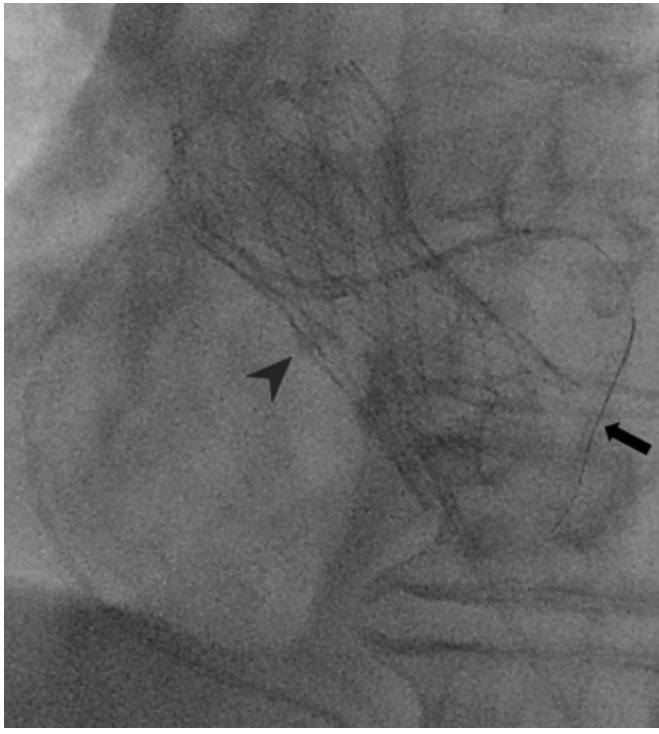

Figure 2. Left anterior oblique view of angiogram showed an oversizing 26mm self-expanding valve (CoreValve EvoR; Medtronic) (arrowhead) was placed with left main wire protection (arrow) in order to prevent coronary obstruction.

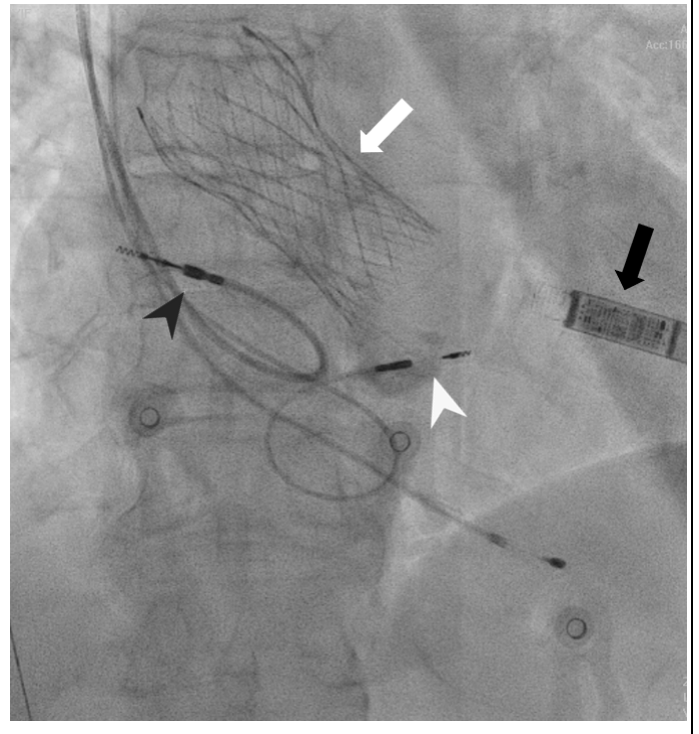


Figure 3. An ILR (LINQ; Medtronic) (black arrow) was implanted after self-expanding valve (CoreValve EvoR; Medtronic) placement (white arrow). A PPM (Advisa™ DR MRI SureScan™; Medtronic) was implanted with left bundle branch area pacing (white arrowhead) and atrial lead (black arrowhead).

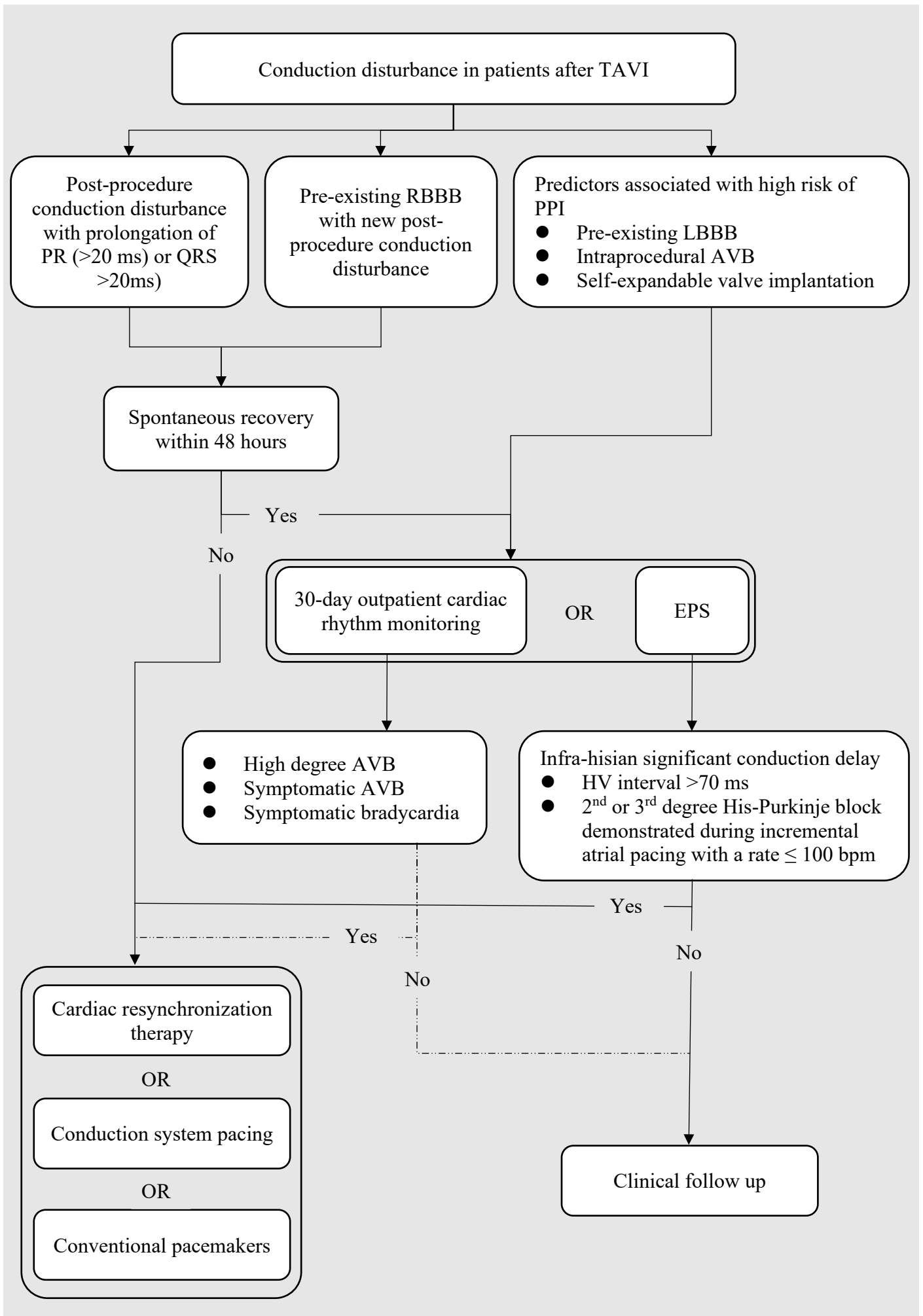


Figure 4. Management flowchart for new conduction disturbance in patients after TAVI.