

中文題目：急性腦梗塞患者的橫紋肌溶解症與肝功能異常

英文題目：Rhabdomyolysis and elevated transaminases in acute cerebral infarction

作者：王耀新<sup>1</sup>，嚴介聰<sup>2</sup>，陳彥均<sup>1,3</sup>

服務單位：<sup>1</sup>大林慈濟醫院內科部；<sup>2</sup>大林慈濟醫院神經內科；<sup>3</sup>大林慈濟醫院腸胃內科

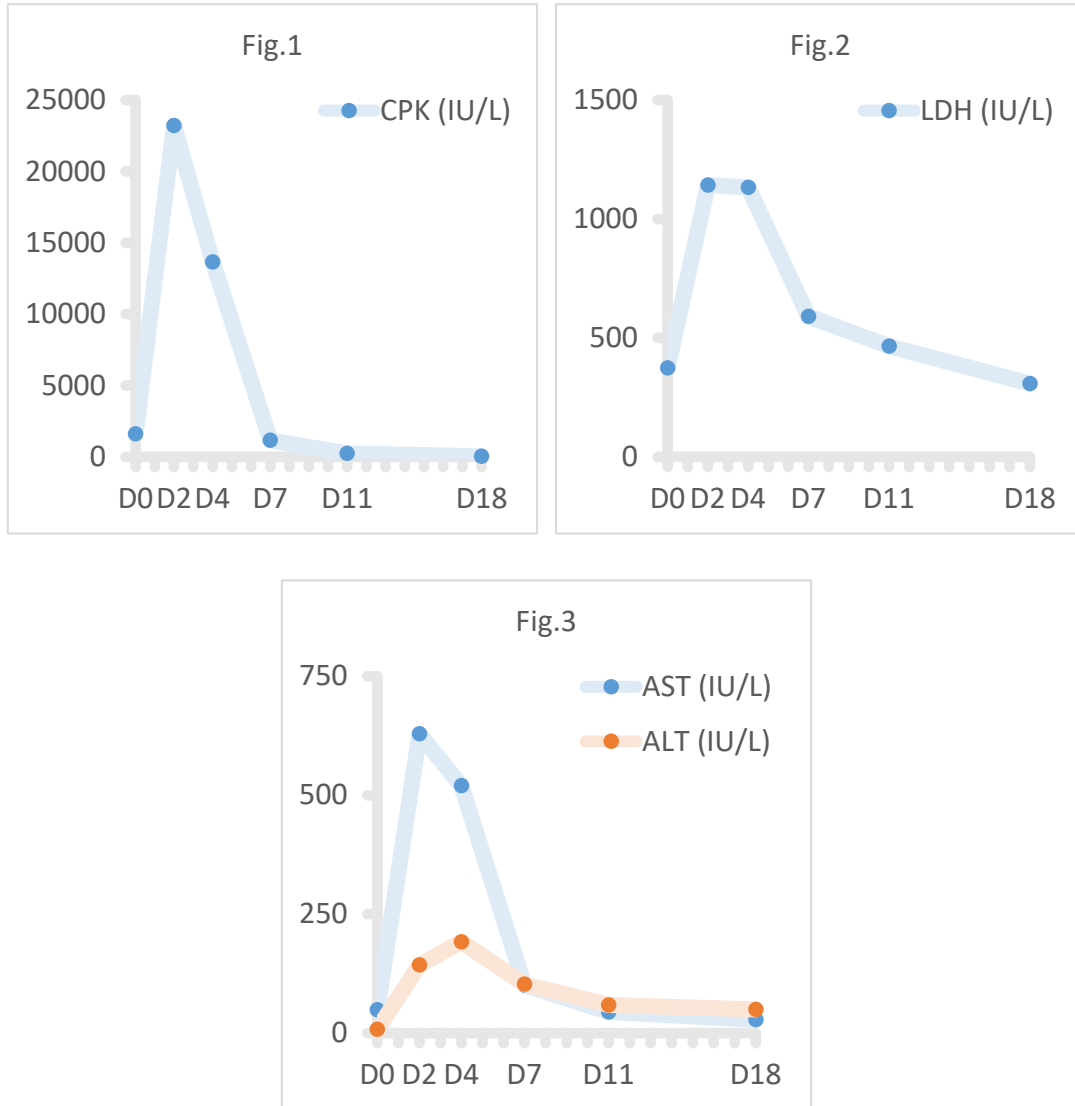
### **Introduction :**

Rhabdomyolysis is the breakdown of myocytes of skeletal muscle and the release of intracellular contents into the bloodstream. The potential causes include trauma, crush injuries, drugs, toxins, prolonged immobilization, compartment syndrome, marked exertion in untrained individuals, hyperthermia, medications or infections. We here describe a case of rhabdomyolysis and elevated transaminases in a 77-year-old man with acute cerebral infarction.

### **Case presentation :**

A 77-year-old man with hypertension presented with a complaint of alterations in consciousness for one day. Twenty hours prior to presentation, he complained dizziness and her daughter noticed he had unsteady gait. Fifteen hours prior to presentation, he told the superintendent of the apartment building that he felt so dizzy and wanted to take a rest. Two hours prior to presentation, his daughter found him unconsciousness, lying on the flooded floor of the bathroom. After his daughter awakened him, he could not recognize her but he could say his name. His daughter noticed he had slurred speech, general weakness, and focal swellings over his forehead and right elbow. His daughter denied he had fever, alcohol consumption, or involuntary muscle movements. He was taken to our hospital immediately. On initial evaluation in the emergency department, his Glasgow Coma Scale was E4V4M5 and his vital signs were T: 36.6, P: 91, R: 17, BP: 157/97, and SpO<sub>2</sub>: 96%. On examination, the patient had dysarthria and there was no obvious neurologic deficit otherwise. Brain CT showed no acute intracranial hemorrhage or obvious hypoattenuation. Blood test demonstrated elevated creatine phosphokinase, elevated troponin I, elevated lactate dehydrogenase, elevated myoglobin, elevated transaminases, unconjugated hyperbilirubinemia, hyperammonemia, and prerenal azotemia. Urinalysis showed OB 2+, RBC 3-5/HPF, ketonuria, increased urine urobilinogen, and increased urine specific gravity. Toxicology screening for drugs of abuse showed ethanol <10 mg/dl, negative urine amphetamine and negative urine morphine. Blood test for acute hepatitis survey showed negative HBs Ag, positive HBc IgG, and negative anti-HCV. Abdominal echo showed liver cirrhosis with mild splenomegaly. The peak values of CPK occurred on day 2. There was acute kidney

injury with oliguria. After adequate hydration, the elevated laboratory test results were gradually improved (Fig.1-3) and his consciousness was improved. Brain MRI showed lacunar infarcts at left basal ganglion. EEG showed slow alpha wave, which indicated diffuse cerebral dysfunction. We arranged neuro-rehabilitation and acupuncture. After treatment, his dysarthria was gradually improved. He was discharged from hospital in a stable condition.



### Discussion :

A study[1] examined the incidence and clinical spectrum of rhabdomyolysis in neurologic disorders. There is 34.7% of epilepsy followed by 19.8% of stroke in a total of 248 patients with rhabdomyolysis. The authors speculate that continued unrestricted muscle contraction during seizures, and immobility after stroke, are likely the cause of rhabdomyolysis in those subsets of patients.

Abnormal liver function tests are frequently observed in cases of severe rhabdomyolysis, which raises the suspicion of liver injury and often triggers a

subsequence of investigation[2]. AST is found in the liver, cardiac muscle, skeletal muscle, and other organs. ALT is more specific to the liver but also found in skeletal muscle in much lower concentrations[2]. A retrospective study[3] demonstrated the incidence of abnormal AST was 93.1% in the 215 cases of rhabdomyolysis with CPK of more than or equal to 1000 U/L and abnormal ALT was found in 75.0% of the patients. Furthermore, serial AST concentrations fall in parallel with CPK concentrations but ALT does not fall as rapidly as AST.

### **Conclusion :**

In conclusion, rhabdomyolysis should be considered in the differential diagnosis in patients with a rise in aminotransferases. A concomitant elevation followed by improvement in liver enzymes with CPK is highly suggestive of rhabdomyolysis. In addition, rhabdomyolysis is shown to occur in epilepsy and stroke. Diagnostic evaluation should be obtained in those patients who have typical symptoms or have a recent exposure to the potential events. Laboratory tests should be followed up since the rise of the enzymes may not be detectable immediately after the inciting injury. Early vigorous fluid resuscitation helps in repletion of hypovolemia, correction of electrolytes imbalance, clearance of CPK, and protection against nephrotoxicity.

### **References :**

1. Paternostro, C., Gopp, L., Tomschik, M., Krenn, M., Weng, R., Bointner, K., Jäger, F., Zulehner, G., Rath, J., Berger, T., Zimprich, F., & Cetin, H. (2021). Incidence and clinical spectrum of rhabdomyolysis in general neurology: a retrospective cohort study. *Neuromuscular disorders: NMD*, 31(12), 1227–1234. <https://doi.org/10.1016/j.nmd.2021.09.012>
2. Lim A. K. (2020). Abnormal liver function tests associated with severe rhabdomyolysis. *World journal of gastroenterology*, 26(10), 1020–1028. <https://doi.org/10.3748/wjg.v26.i10.1020>
3. Weibrecht, K., Dayno, M., Darling, C., & Bird, S. B. (2010). Liver aminotransferases are elevated with rhabdomyolysis in the absence of significant liver injury. *Journal of medical toxicology: official journal of the American College of Medical Toxicology*, 6(3), 294–300. <https://doi.org/10.1007/s13181-010-0075-9>