

中文題目：老鼠咬傷引起多發感染性關節炎之個案病例報告

英文題目：Rat-bite Fever Complicated with  
Multiple Septic Arthritis: A case report

作者：吳美美，葉沐蒼，杜希蓉

服務單位：高雄市天主教聖功醫院內科

**Abstract:**

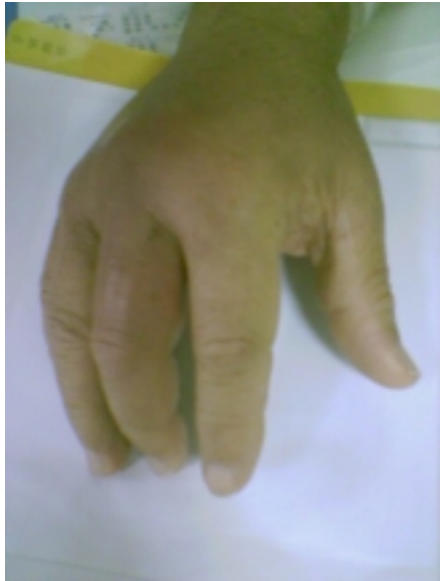We present this patient who came to our clinic due to right ankle pain, he was thought to have gouty arthritis. However, after three days of treatment there were no signs of improvement. To make things worse, he has developed multiple painful joint swelling. Our patient also has history of recent travel to Japan, and intermittent residence in rural area of Taiwan, which has complicated our diagnosing process. We have finally linked this

multiple septic arthritis to incidence of rat-bite two weeks before at the right hand knuckle.

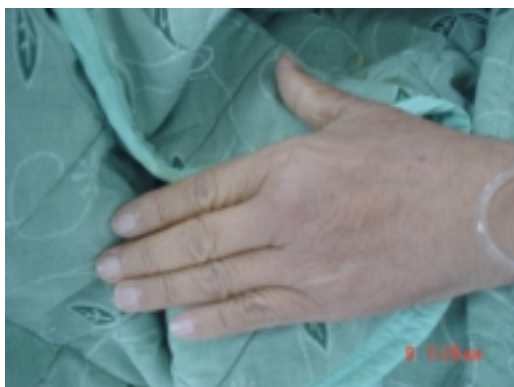### **Case Report:**

This 63-year old male patient who suffered from fever for two weeks prior to admission was brought to our clinic. The initial impression was right ankle gouty arthritis. His history includes left renal stone, alcoholism which began three decades ago, and quit for 10 years, and rat-bite over right knuckle **(Picture 1)** two weeks ago. He was traveling in Japan on initial fever onset, and returned to rural Ping-Tung (屏東縣) when fever recurred. His monoarthritis soon turned multiple **(Picture 2-5)**, which included the right sternalclavicular joint **(Picture 6)**, that was the most painful and debilitating. Laboratory data revealed mild leukocytosis, elevated liver functions, X-ray of joints has not revealed bony lesion. Right ankle pus smear showed **(Picture 7)**. With antibiotics

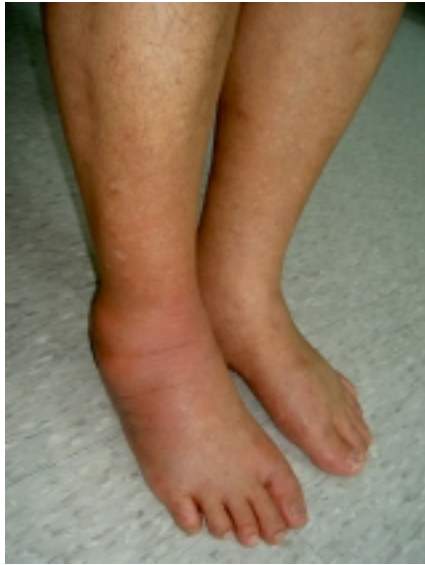(Cefazolin + Clindamycin → Penicillin) and right ankle joint arthrotomy for irrigation and drainage (Picture 8), his condition improved dramatically.



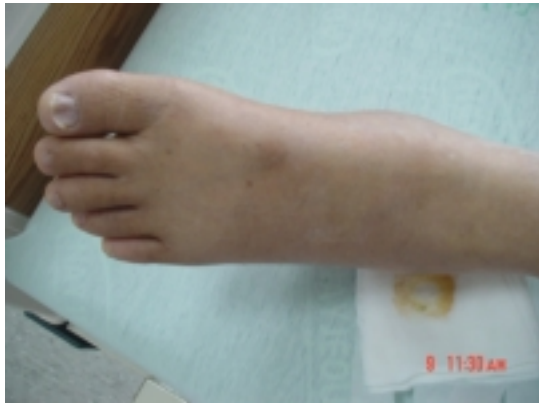**Picture 1: Right knuckle bite wound and arthritis**



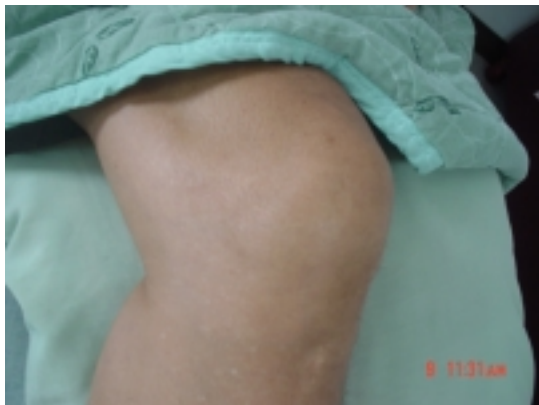**Picture 2: Left knuckle arthritis**



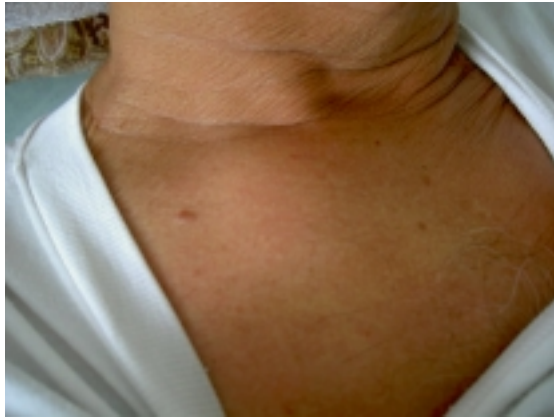**Picture 4: Left ankle arthritis**



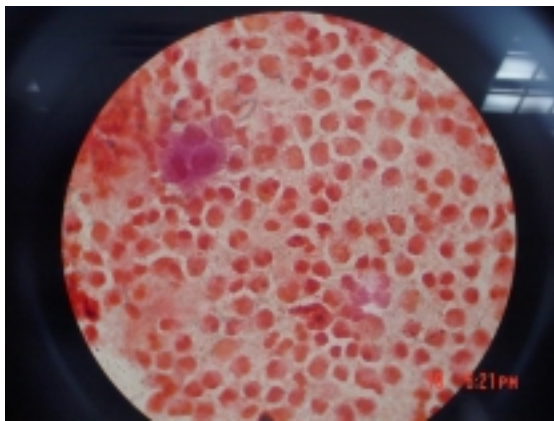
**Picture 3: Right ankle arthritis**



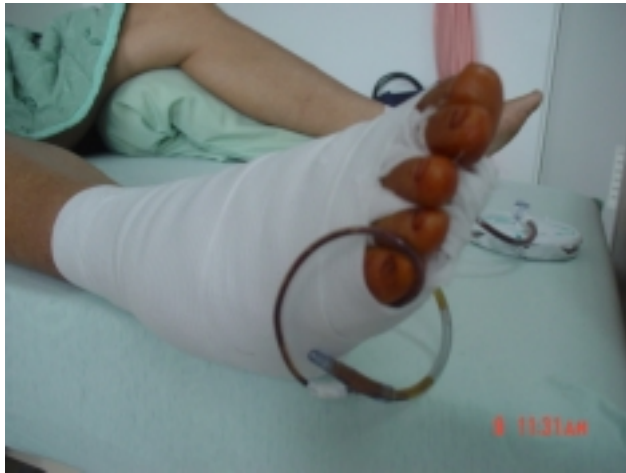**Picture 5: Left knee arthritis**



Picture 6: Right sternoclavicular joint swelling



Picture 7: Pus Gram stain smear: many white blood cells but no organism seen



**Picture 8: Right ankle s/p drainage**

**Discussion:**

Rat-bite fever (RBF) is also known as Streptobacillary fever, Streptobacillosis, Haverhill fever, Epidemic arthritic erythema, Spirillary fever, and Sodoku in Japan. It is caused by *Streptobacillus moniliformis* (Gram negative rod) and *Spirillum minus* (Gram negative spiral), found at normal respiratory tract of rats. History of rat-bite has been reported in most cases, however about 30 percent of patient has not been bitten. In 1926, there was an outbreak in Haverhill, Massachusetts where 86 persons were infected due to ingested of

contaminated unpasteurized milk. In 1983 outbreak, 304 boarding school children occurred in Chelmsford, England due to water contamination. Thus, rat-bite is not necessary for rat-bite fever for develop.

In this particular case, we have obtained discharge smear on early management. *S. moniliformis* is diagnosed only by blood culture. Unfortunately, our blood culture didn't yield despite prolong incubation; agglutination test was not available at our hospital. Usually, dark-field preparation from blood, exudates from lesion or adjacent lymph nodes can identify *S. minus*, it exhibits darting motility.

Although *S. minus* is more common in Asia, we favor *S. moniliformis* as our infected organism due to its frequent cause of large joint involvement. *S. minus* frequently cause a particular skin rash characterized by red or purple plaques

Penicillin is the drug of choice. Alternative drugs include Doxycycline or tetracycline. Prolonged treatment should be considered with joint involvement.