

A CASE OF SHAPIRO'S SYNDROME TREATED SUCCESSFULLY WITH CLONIDINE

Chetan Shenoy

Department of Internal Medicine

Guthrie/Robert Packer Hospital, Sayre, Pennsylvania, USA

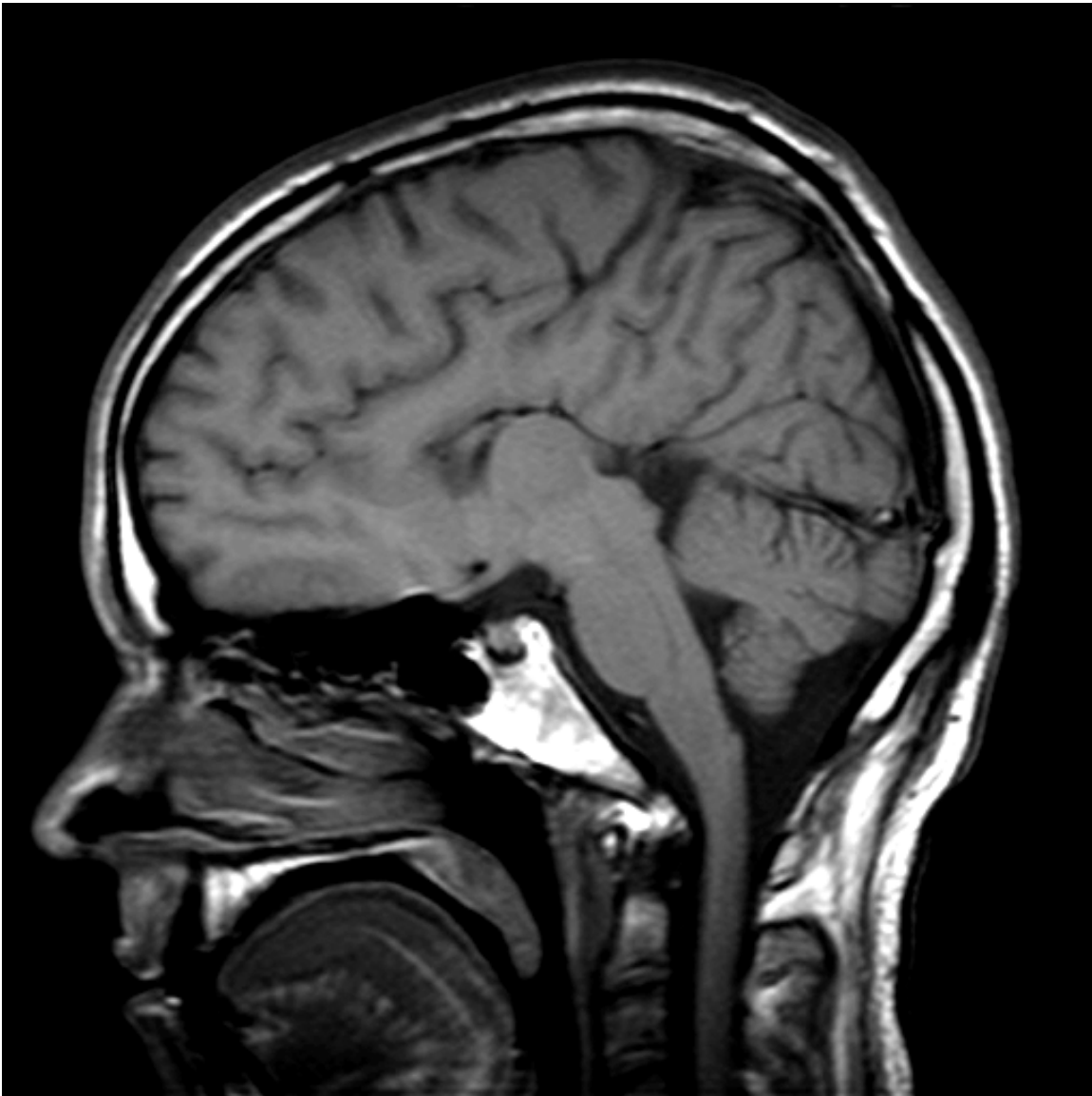
BACKGROUND: Agenesis of the corpus callosum is a common congenital anomaly which occurs in upto 0.3 percent of normal individuals. Shapiro's syndrome is a rare presentation of callosal agenesis with associated episodic hyperhidrosis and hypothermia, of which there are only about 30 cases reported in the literature. There is no definite data about the treatment of the syndrome due to its rarity. Clonidine has been used with good results in a few recent cases. We describe our experience with a case of Shapiro's syndrome treated with clonidine.

CASE REPORT: A 34-year-old Caucasian male was presented with lethargy, confusion, episodic chills and profuse sweating of two months duration, associated with a 20-lb (9-kg) weight loss. Physical examination revealed delirium, significant diaphoresis, hypothermia with a core temperature of 89.9°F (32.1°C) and signs of dehydration. Laboratory testing revealed electrolyte disturbances consistent with dehydration. The leukocyte count, blood glucose, thyroid function and cortisol were normal, and the drug screen was negative. He was initially treated with warm blankets and vigorous volume replacement. A central cause of the hypothermia was suspected and Magnetic Resonance Imaging of the brain was obtained, which revealed the complete absence of the corpus callosum. Shapiro's syndrome was recognized and he was started on clonidine 100 micrograms every 8 hours. His mental status, electrolyte and renal disturbances resolved over the next three days. He did not develop any further episodes of hypothermia and hyperhidrosis, and continued to be asymptomatic a year later.

DISCUSSION/CONCLUSIONS: Clonidine, at a dose of 100 micrograms every 8 hours is an effective treatment for Shapiro's syndrome. It has been proposed to work by resetting the hypothalamic thermoregulatory set-point.

Keyword: Callosal Agenesis, Hypothermia, Shapiro's Syndrome

Sagittal



T1-weighted MRI of the brain showing complete agenesis of the corpus callosum in our patient with Shapiro's Syndrome.