

Disseminated *Mycobacterium kansasii* infection in HIV negative patient misinterpreted with malignancy in clinical practice and PET/CT scan

Jao-Hsein Wang ¹ , Chi-hue Chu ²

¹ Medical Department , Jiannren Hospital, Kaohsiung, Taiwan

² Laboratory Department , Jiannren Hospital, Kaohsiung, Taiwan

Abstract

A case of right neck lymph node adenopathy accompanied with progressive body weight loss. Malignancy was highly suspected. PET showed increased FDG uptake over the whole body. Excision biopsy was done and the pathology showed chronic granulomatous inflammation and positive acid-fast stain. The biopsy culture grew *Mycobacterium kansasii*. Anti-tuberculous therapy was performed for six months. Repeated PET scan revealed complete remission of uptake. In Taiwan, there is a high prevalence of tuberculosis and nontuberculous mycobacterial (NTM) infection; the possibility of misinterpretation should be considered when PET scans of patients disclosed highly suspicious malignancy. .

Case report

A 68-year-old man had malaise, body weight loss and enlarged right cervical lymph nodes. He was admitted at one medical center and received surgical

excision biopsy. The biopsy showed granulomatous inflammation with negative acid-fast bacillus (AFB) staining. He was diagnosed to have extra-pulmonary tuberculosis and was treated with standard anti-tuberculosis drugs (Isoniazid + Rifampin + Ethambutol + Pyrazinamide) for one month. Because of persistent progressive body weight loss and relapse of right neck lymph node adenopathy, he was admitted to our hospital. The initial impression was the high suspicion of occult malignancy due to poor response to anti-tuberculous drugs. F-18 FDG PET/CT scan was arranged. The PET/CT scan showed hot FDG uptake in right cervical lymphadenopathy and multiple bony lesions without obvious destruction involving spine, rib cage, shoulders, pelvic bones and femora (**Fig 1**) Initial report was multiple bony metastasis, the source was undetermined. So a lymph node and bone marrow repeat biopsy was performed; the pathology revealed granulomatous inflammation and positive Acid fast stain for Mycobacteria. (**FIG 2**) The neck lymph node culture grew *Mycobacterium kansasii*. After another six months anti-tuberculosis therapy (Isoniazid + Rifampin + Ethambutol + clarithromycin) . a repeat PET/CT scan showed remission of prior lesions. (**FIG 3**) After anti-tuberculosis therapy for nine months, the general condition was much improved including the body weight loss and malaise

Conclusion:

In Taiwan, the high prevalence of tuberculosis was noted. Disseminated *Mycobacterium kansasii* in HIV negative patient with multiple bony involvement was rare. Both diseases with PET scan showed increase uptake. We should keep in mind with the possibility of misinterpretation in PET scans of patients with malignancy, especially in Taiwan.

Figure 1. F-18 FDG PET/CT showed increased FDG uptake in right cervical enlarged lymph nodes and multiple bony lesions without obvious destruction involving spine, rib cage, shoulders, pelvic bones and femora.

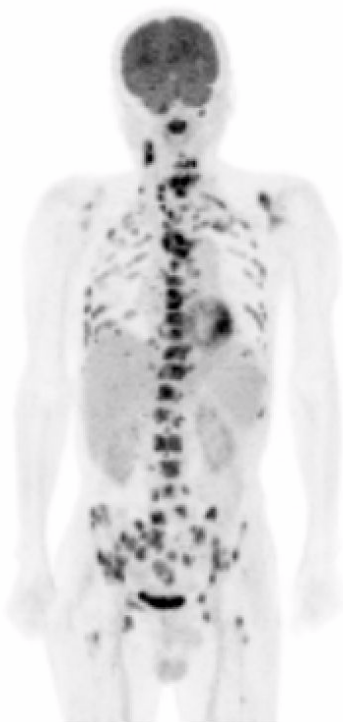


Figure 2. Bone marrow and right neck lymph node biopsy, the pathology showed chronic granulomatous inflammation and multinucleated giant cells, the acid fast bacilli are identified on ziehl-neelsen stain

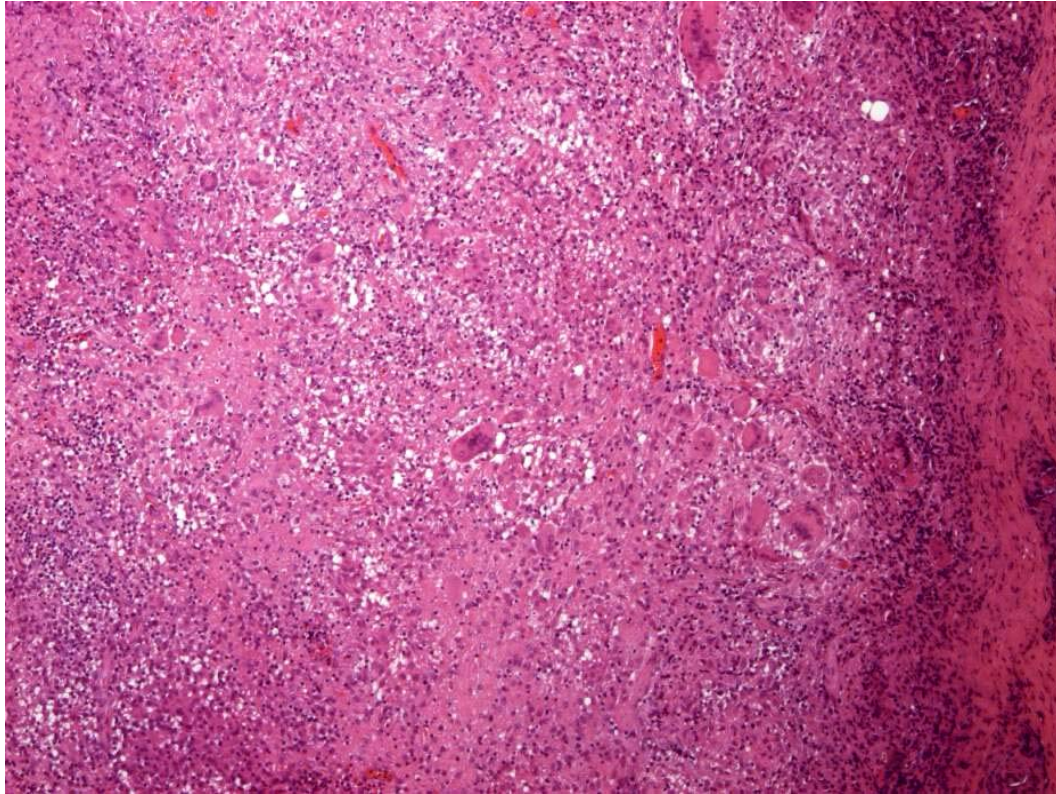


Figure 3. A repeat FDG/CT scan 6 months later showed remission of prior FDG-avid lesions in right neck and bones.

