

Familial Hypercholesterolemia and Xanthomatosis Associated with Diabetes Mellitus:
A Case Report and Review of the Literature

Ching-Hsiang Leung, Tien-Ling Chen*, Chao-Hung Wang,
Kun-Wu Tsan, and Daniel T. H. Chin**

Division of Endocrinology and Metabolism, Department of Internal Medicine;

*Division of Allergy, Immunology & Rheumatology,

Department of Internal Medicine;

**Department of Pathology;

Mackay Memorial Hospital, Taipei, Taiwan

Abstract

Familial hypercholesterolemia is an autosomal dominant disorder due to mutations in the low-density lipoprotein receptor gene, characterized by skin and tendon xanthomas, xanthelasma and premature arcus corneae. It is associated with an increased risk of premature coronary heart disease, which is further increased if there is co-existing diabetes mellitus. A 35-year-old female who developed cutaneous and tendon xanthomas since the age of 12 was diagnosed as having mixed primary familial hypercholesterolemia and secondary hyperlipidemia due to diabetes mellitus, and osteomyelitis. However, familial hypercholesterolemia remains seriously under-diagnosed, delaying treatment. Screening of first-degree relatives and extended family members plays an important role in early detection and treatment. (J Intern Med Taiwan 2003;14:23-30)

Key Words : Familial hypercholesterolemia, Xanthomatosis, Diabetes mellitus, LDL receptor, Osteomyelitis

Introduction

Familial hypercholesterolemia is a monogenic ¹, autosomal dominant ² disorder due to mutations in the gene for the LDL receptor ³, characterized by xanthomas ⁴, xanthelasma and premature arcus corneae ⁵. Our report concerns a 35-year-old female patient who developed xanthomas since the age of 12 and was diagnosed as having mixed primary familial hypercholesterolemia and secondary hyperlipidemia due to diabetes mellitus, and osteomyelitis. The significance, characteristic features, diagnosis and treatment of familial hypercholesterolemia are

discussed.

Case Report

A 35-year-old female developed weight loss of more than 10 kg over one month, accompanied by poor appetite, polyuria and polydipsia. She also had a one-month old non-healing wound over her right foot, persistent left thigh and knee pain and swelling for a few weeks and mild fever for one week. She visited our endocrinology OPD, hyperglycemia was detected (random blood glucose: 586 mg/dl) and she was admitted for further evaluation and treatment.

On questioning the patient, it was found that she is the fourth in a family of 5 children and is a teetotaler. There was no history of consanguinity. Her father, who developed diabetes at the age of 50 and died due to acute myocardial infarction at the age of 75 years, did not have hypercholesterolemia. Her mother has both xanthelasma and hypercholesterolemia, but no diabetes mellitus. Her eldest sister and both brothers have hypercholesterolemia. Only one sister does not have hypercholesterolemia. Her pedigree is shown in Fig. 1.

She had a past history of multiple nodules, initially developing over both elbows and knees at the age of 12 years, and then occurring over the knuckles of the hands, buttocks and feet for the last 6 years. She sought medical evaluation at the age of 20, and was diagnosed as having hypercholesterolemia. She took lipid lowering drugs for 2 years, but then stopped as the lesions did not subside. She had no past history of diabetes mellitus.

On examination, she was of average build and her height was 160 cm, blood pressure was 120/70 mm Hg, pulse 130/minute, temperature 37.1°C and respiratory rate 24/min. There was no xanthelasma or arcus corneae.

There were multiple yellowish papules over the trunk, nape of her neck and both forearm flexures, and large eruptive plaques (xanthomas) over both knees and buttocks. Xanthomas were also present over both elbows and some of the metacarpo-phalangeal joints of both hands. Both Achilles tendons and some hand and feet extensor tendons were thickened and had tendon xanthomas. These are seen in figs. 2 and 3.

There was mild swelling, warmth and tenderness of the left thigh and knee with movement limitation, but no erythema. She also had an ulcer over the dorsum of the right foot and a swelling over the dorsum of the left foot.

Investigations revealed poorly controlled diabetes mellitus (fasting blood glucose: 344 mg/dl, post-prandial blood glucose: 260 mg/dl, HbA1c: 16.1%) and hyperlipidemia (total cholesterol (TC): 510 mg/dl (normal: 130-230 mg/dl), triglyceride (TG): 245 mg/dl (normal: 35-165 mg/dl), low density lipoprotein cholesterol (LDL-C): 421

mg/dl (normal: 0-150 mg/dl) and high density lipoprotein cholesterol (HDL-C): 55 mg/dl). There was mild leucocytosis (white blood cell count: $11.7 \times 10^3/\text{mm}^3$, band: 0%, neutrophils: 90%), markedly elevated ESR [109 mm/hr in the first hour (normal: 0-20)] and elevated C-reactive protein (CRP) [16.5 mg/dl (normal: <0.8)]. Thyroid function tests showed low T3 syndrome [T3: 72.5 ng/dl (normal: 100.0-190.0 ng/dl), free T4: 0.6 ng/dl (normal: 0.5-2.0 ng/dl) and TSH: 1.6 $\mu\text{IU}/\text{ml}$ (normal: 0.5-5.2 $\mu\text{IU}/\text{ml}$). Other lab investigations including hemoglobin concentration, platelet count, liver and renal functions, serum uric acid and serum electrolytes were within normal.

Electrocardiography showed sinus tachycardia and non-specific ST-T changes. Cardiac echo revealed mitral valve prolapse, moderate pulmonary regurgitation, mild tricuspid regurgitation and mitral regurgitation.

Ultrasonography of the legs revealed multiple xanthomas, including as xanthomas over both Achilles tendons. The maximum anteroposterior diameter of the Achilles tendon was 14 mm. On electromyography, the left gastrocnemius and left vastus lateralis showed severe denervation changes with poor reinnervation.

X-ray of the left knee and femur revealed a well-defined, mixed-density lesion with a sclerotic margin over the distal femoral metaphysis. Magnetic resonance imaging (MRI) of the left leg showed a benign lesion and osteomyelitis over the distal end of the left femur, and extensive myositis of the left thigh, as shown in fig. 4. There were xanthomas over the patellar, tibialis anterior, peroneus and Achilles tendons, and myositis and fasciitis of the lower leg muscles. MRI of xanthomas in the Achilles and peroneus tendons is shown in fig. 5. Open biopsy of the left distal femur and distal femoral mass revealed osteomyelitis.

Biopsy of the nodules over the skin of the dorsum of the hand and left lower leg revealed xanthoma. The epidermis showed reactive acanthosis and foamy histiocytes in the dermis. Other findings included cholesterol clefts and fibrosis. These findings are shown in figs. 6 and 7.

Debridement was performed for her right foot ulcer and wound culture revealed salmonella group C organisms. However, three sets of blood culture were all negative. Osteomyelitis was treated with ceftriaxone for six weeks. Aspiration of the mass over her left foot revealed salmonella group C organisms. Her right foot ulcer healed and skin graft was done later for the skin defect.

Blood sugar was initially controlled by insulin and later changed to oral hypoglycemic agents. Hyperlipidemia was treated with atorvastatin and cholestyramine.

Fever subsided and her white cell count became normal. ESR was 21 mm/hr in the

first hour and CRP normal (0.01) on discharge. After a course of physiotherapy was started, she was able to walk. Body fat analysis done at this stage revealed her weight to be 51.3 kg and body mass index 20.2 kg/m².

On discharge, our patient's fasting blood glucose was 91 mg/dL. Follow-up X-ray of the left femur showed reduced radio opaque density of the lesion compared to the initial x-ray. On OPD follow up five months later, TC was 378 mg/dl, LDL-C 282 mg/dl, HDL-C 79 mg/dl, TG 78 mg/dl and there was a slight decrease in size of the cutaneous xanthomas over the hands and the knees.

Discussion

Hyperlipidemia is caused by increased concentrations of plasma lipoproteins⁵. Alterations resulting from genetic defects are classified as primary disorders of lipoprotein metabolism⁵. Alternatively, other factors that alter lipoprotein metabolism, such as

diabetes mellitus or hypothyroidism, lead to increased plasma lipoprotein concentrations; these are classified as secondary disorders of lipid metabolism⁵.

The triad hypercholesterolemia, xanthomatosis and angina pectoris have been recognized as a dominantly inherited syndrome since the work of Muller (1939)⁶.

Familial hypercholesterolemia (FH) is the classic description made by Drs. Brown and Goldstein of mutations in the gene for the LDL receptor³. To-date, well over 200 mutations have been described³. Plasma levels of LDL-C are elevated at birth and remain so throughout life². Plasma TG levels are typically normal, and HDL-C levels are normal or reduced². FH is associated with a much higher risk for the development of coronary heart disease (CHD) than are other forms of hypercholesterolemia⁷.

FH is a monogenic¹, autosomal dominant disorder that occurs in the heterozygous form in approximately 1 in 500 individuals^{2,5}. Presently, however, the frequency of heterozygous FH in Taiwan is still unknown⁷.

Homozygotes are found approximately 1 in a million^{3,5}. Symptoms of CHD may occur before age 10, and, if not treated, these individuals usually die from myocardial infarction by age 20⁵.

Clinically, FH is characterized by deposits of cholesterol in the vascular wall, causing atheromas, and extravascularly in the form of xanthomas⁴. Other common physical findings in FH include xanthelasma and premature arcus corneae⁵.

Xanthomas ordinarily occur in the skin and tendons of patients with severe hyperlipidemia⁸. Minor trauma plays an important role in the development of xanthomas⁹.

Xanthomas develop because of lipid leakage from the vasculature into the surrounding tissues, where macrophages subsequently phagocytize these lipids 9. Because cholesterol is not degraded, it accumulates within these cells, creating 潤 oamy macrophages 9. The extra cellular cholesterol crystallizes into clefts and includes an inflammatory reaction with giant cells and resultant fibrosis 10. Cutaneous xanthomas may initially present in the intergluteal cleft or in the interdigital spaces on the dorsal surfaces of the hands and feet 11. Planar surfaces over the elbows and knees are other common sites of appearance of xanthomas 11. The characteristic physical finding in 75% of affected individuals of FH is the presence of tendon xanthomas, usually located in the Achilles or the extensor tendons of the hands 5.

Our patient had eruptive, planar and tuberous cutaneous xanthomas, as well as Achilles tendon, lower leg extensor and hand extensor tendon xanthomas. Although xanthomas started appearing at the age of 12, she was investigated and diagnosed with hypercholesterolemia only at the age of 20.

However, up-to 25% of subjects with heterozygous FH do not have xanthomas 5. Sonography is useful in establishing the diagnosis of heterozygous familial hypercholesterolemia in individuals whose cholesterol levels suggest they are at risk for the condition but where Achilles tendons are without clinically apparent xanthomas 12. On sonography, tendons are considered enlarged if the maximum anteroposterior diameter exceeds 7.1 mm, as determined by Steinmetz et al 13.

Approaches to the diagnosis of FH can be clinical (as for the system set up for the Simon Broome Register 14, molecular and cellular 14. According to the Simon Broome Register Group, definite FH is defined as a TC concentration above 7.5 mmol/l (290 mg/dl) or, when available, a LDL-C concentration above 4.9 mmol/l (190 mg/dl) together with the presence of tendon xanthomas either in the patient or in a parent, child, grand parent, sibling, uncle or aunt 14.

Diagnosis of heterozygous FH at birth is best achieved by measuring LDL-C in cord blood¹⁵. However, in clinical practice, the diagnosis of FH is often made presumptively after documentation of an autosomal dominant pattern of inheritance of hypercholesterolemia in affected patients 5. Our patient was diagnosed as having familial hypercholesterolemia according to the guidelines from the Simon Broome Register Group.

Professional and popular awareness of FH is low and it is seriously under diagnosed 16. We could find very few reports concerning familial hypercholesterolemia in Taiwan. According to one such study on FH in Taiwan, the mean age at diagnosis was

older at 51.1 ± 11.9 (36 to 76) years old and most of the patients were female 7.

Effective screening for FH by

cholesterol testing should not be restricted to 1st degree relatives but include everyone in the extended family¹⁷. Testing for DNA mutations may be used to actually find the mutation causing the disorder¹⁷.

Accelerated atherosclerosis frequently occurs in FH resulting in premature CHD and stroke 9. Cicero et al found that in females with heterozygous FH, the primary cause of death was thrombotic stroke (55%, mean age 69 years) 18.

Familial combined hyperlipidemia is associated with elevations of plasma cholesterol and TG levels, however xanthomas or xanthelasma are not a feature 5. Although our patient initially had elevated TC and TG levels, on follow-up TG became and remained normal, but the cholesterol level, although there was a decrease, remained elevated. The initial hypertriglyceridemia was most probably due to diabetic dyslipidemia, which improved after the blood sugar control improved. Hence our patient had mixed primary heterozygous familial hypercholesterolemia and secondary hyperlipidemia due to diabetes mellitus.

Yanagi et al found that in patients with heterozygous FH who were accompanied by diabetes mellitus or impaired glucose tolerance, abnormal glucose metabolism might accelerate the development of CHD due to an increase in the atherogenic remnant lipoprotein in addition to high concentration of LDL¹⁹. Hence, family members of diabetic patients having xanthelasma, premature arcus corneae and xanthomas merit screening for detection of familial hypercholesterolemia.

Treatment of heterozygous FH consists of a diet low in total and saturated fat (approximately 20% and 6% of calories, respectively) and low in cholesterol (<100 mg/d) and, in most cases, combined drug therapy 5. Diabetes is considered a CHD equivalent according to the NCEP released ATP III guidelines in May 2001²⁰. Special attention should be paid in the treatment of FH patients with impaired glucose metabolism, to avoid the advancement of coronary atherosclerosis 19. Since our patient has both FH and diabetes, aggressive lipid lowering is crucial, even at a young age.

Effective drug combinations usually include low doses of bile acid sequestrants together with HMG-CoA reductase inhibitors or niacin or all these agents combined 5. Recently, a new third generation statin, rosuvastatin demonstrated significantly greater reduction in LDL-C as well as significantly greater increase in HDL-C compared to atorvastatin 21. In patients with homozygous FH and in ordinary FH patients who respond poorly to diet and drug therapy, LDL-apheresis can cause profound lowering of LDL-C levels 4.

Our patient had left thigh and knee pain and swelling. An association exists between

FH and musculoskeletal symptoms such as arthritis and tendinitis 22. Hence the differential diagnosis included arthritis, tendinitis, neuropathic osteoarthropathy or an infectious process such as osteomyelitis. Her left thigh and knee pain and swelling were proved to be due to myositis, fasciitis and osteomyelitis.

Osteomyelitis is present in a substantial portion of limb-threatening infections in patients with diabetes and the risk of amputation is much higher than in patients without diabetes 23. Overall, MRI is reported to be the most specific and sensitive imaging test for diagnosing osteomyelitis in patients with diabetes and foot ulcers 24. Parenteral antibiotics may be administered initially, followed by a 2-to-6 week course of oral agents, providing a total of 6-12 weeks of treatment 25.

Conclusion

FH is a monogenic, autosomal dominant disorder caused by mutations in the LDL receptor gene. It is characterized by cutaneous and tendon xanthomas, xanthelasma and premature arcus corneae, and is associated with an increased risk of coronary heart disease; and this risk is further increased if there is co-existing diabetes mellitus. However, it remains seriously underdiagnosed, resulting in delayed treatment. Screening of first-degree relatives and extended family members plays an important role in early detection and treatment. Aggressive treatment of hypercholesterolemia including diet control, lipid lowering drugs, exercise and control of risk factors will help to reduce the morbidity and mortality associated with this disease. Arthritis, tendinitis and osteomyelitis should be included in the differential diagnosis of patients with familial hypercholesterolemia and diabetes mellitus presenting with limb and joint pain and swelling.

References

1. Goldstein JL, Brown MS. Familial hypercholesterolemias. In: Stanbury JB, Wyngaarden JB, Fredrickson DS, Goldstein JL, Brown MS, eds. Metabolic basis of inherited diseases. New York: McGraw-Hill, 1989; 1129-64.
2. Ginsberg HN, Goldberg IJ. Disorders of lipoprotein metabolism. In: Braunwald E, Fauci AS, Kasper DL, Hauser SL, Longo DL, Jameson JL, eds. Harrison's principles of internal medicine. 15th ed. New York: McGraw-Hill, 2001, 2245-57.
3. Hsia SH. Disorders of lipid metabolism. In: Lavin N, ed. Manual of endocrinology & metabolism. 3rd ed. Philadelphia: Lippincott Williams & Wilkins, 2002; 520-47.
4. Buja LM, Kovanen P, Bilheimer DW. Cellular pathology of homozygous familial hypercholesterolemia. Am J Pathol 1979; 97: 324-58.
5. Manley RW, Weisgraber KH, Farese RV. Disorders of lipid metabolism. In: Wilson

- JD, Foster DW, Kronenberg HM, Larsen PR, eds. Williams textbook of endocrinology. 9th ed. Philadelphia: W.B. Saunders Co., 1998; 1099-153.
- 6.Heiberg A, Berg K. The inheritance of hyperlipoproteinaemia with xanthomatosis: a study of 132 kindreds. *Clinical Genetics* 1976; 9:203-33.
- 7.Chung MH, Chen KW, Chen JF, Lu WT, Sun JH, Lin JD. Identification of familial hypercholesterolemia in Taiwan: report of eleven cases. *Chang Gung Med J* 1999; 22: 460-7.
- 8.Witztum J, Steinberg D. Disorders of lipid metabolism. In: Bennett JC, Plum F, eds. *Cecil textbook of Medicine*. 20th ed. Philadelphia: W.B. Saunders Co., 1996; 1086-95.
- 9.Bonhomme GR, Loevner LA, Yen DM, et al. Extensive intracranial xanthoma associated with type II hyperlipidemia. *AJNR* 2000; 21:353-5.
- 10.Jackler RK, Brackmann DE. Xanthoma of the temporal bone and skull base. *Am J Otol* 1987; 8: 111-5.
- 11.Sprecher DL, Schaefer EJ, Kent KM, et al. Cardiovascular features of homozygous familial hypercholesterolemia: analysis of 16 patients. *Am J Cardiol* 1984; 54: 20-30.
- 12.Bude RO, Nesbitt SD, Adler RS, Rubenfire M. Sonographic detection of xanthomas in normal-sized Achilles tendons of individuals with heterozygous familial hypercholesterolemias. *AJR* 1998; 170: 621-5.
- 13.Steinmetz A, Schmitt W, Schuler P, Kleinsorge F, Schneider J, Kaffarnik H. Ultrasonography of Achilles tendon in primary hypercholesterolemia: comparison with computed tomography. *Atherosclerosis* 1988; 74: 231-9.
- 14.Betteridge DJ for the Simon Broome Register Group. Risk of fatal coronary heart disease in familial hypercholesterolemia. *Br Med J* 1991; 303: 893-6.
- 15.Primary hypercholesterolemia. In: Thompson GR, ed. *In: A handbook of Hyperlipidemia*. Revised ed. London: Current Science Ltd; 1994; 111-25.
- 16.Winder AF. On the diagnosis of heterozygous familial hypercholesterolemia. *Int J Cardiol* 2000; 74: 13-4.
- 17.Kastelein JJP. Screening for familial hypercholesterolemia: effective safe treatments and DNA testing make screening attractive. *BMJ* 2000; 321: 1483-4.
- 18.Cicero AFG, Braiato A, D'Addato S, Sangiorgi Z, Gaddi A. A suggestion of familial hypercholesterolemia heterozygosity clinical diagnosis based on epidemiological observations in a large Italian population. *Int J Cardiol* 2000; 74: 5-11.
- 19.Yanagi K, Yamashita S, Kihara S, et al. Characteristics of coronary artery disease and lipoprotein abnormalities in patients with heterozygous familial hypercholesterolemia associated with diabetes mellitus or impaired glucose tolerance. *Atherosclerosis* 1997; 132: 43-51.

20. Expert panel on detection, evaluation, and treatment of high blood cholesterol in adults: executive summary of the third report of the national cholesterol education program (NCEP) expert panel on detection, evaluation, and treatment of high blood cholesterol in adults (Adult Treatment Panel III). JAMA 2001; 285: 2486-97.
21. Davidson MH. Rosuvastatin: a highly efficacious statin for the treatment of dyslipidemia. Expert Opin Investig Drugs 2002; 11 : 125-41.
22. Ball EV. Systemic diseases in which arthritis is a feature. In: Bennett JC, Plum F, eds. Cecil textbook of Medicine. 20th ed. Philadelphia: W. B. Saunders Co., 1996; 1525-30.
23. Karchmer AW, Gibbons GW. Foot infections in diabetes: evaluation and management. Curr Clin Top Infect Dis 1994; 14: 1-22.
24. Bonham P. A critical review of the literature: diagnosing osteomyelitis in patients with diabetes and foot ulcers. JWOCN 2001; 28: 73-88.
25. Bonham P. A critical review of the literature: antibiotic treatment of osteomyelitis in patients with diabetes and foot ulcers. JWOCN 2001; 28: 141-9.

家族性高膽固醇血症及黃色瘤合併糖尿病

梁清香 陳天令* 王朝弘 詹錕鋁 秦達孝**

台北馬偕紀念醫院 內科部內分泌暨新陳代謝科

*內科部過敏免疫風濕科 **病理科

摘 要

家族性高膽固醇血症是一種自體顯性遺傳的疾病，主要是由於低密度脂蛋白接受器的基因突變所造成，表現出來的特徵，有皮膚、肌腱的黃色瘤，黃色瘤斑及早發性角膜弓。此疾病是早發性冠狀動脈疾病高危險群，若有糖尿病，機率更高。一位三十五歲的女性患者，從十二歲就發現有皮膚和肌腱的黃色瘤產生。她被診斷為混和型的原發性家族高膽固醇血症，及糖尿病造成的次發性高脂血症和骨髓炎。然而家族性高膽固醇血症診斷率還是很低，導致延遲治療，因此對一等血親以及其他家族成員的篩檢，在早期偵測上就扮演了一個重要的角色。

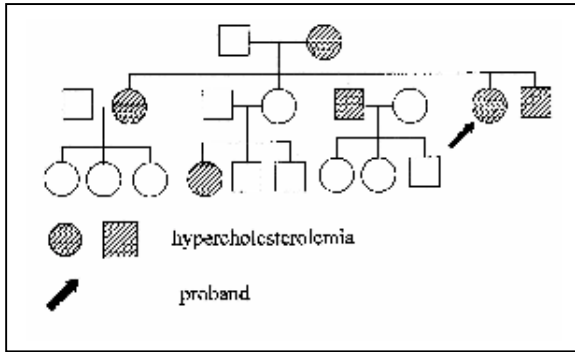


Fig.1. Pedigree of patient.

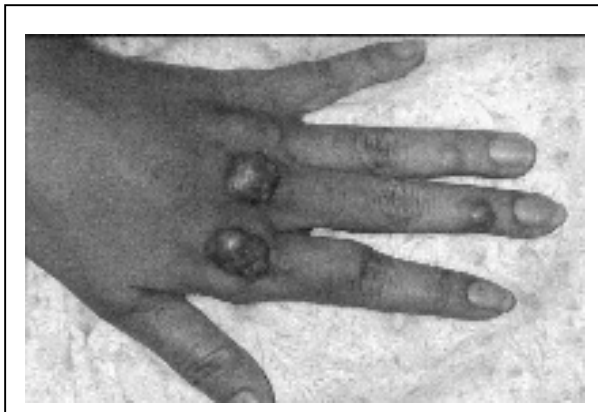


Fig.2. Tuberosus and tendon xanthomas on the hand.

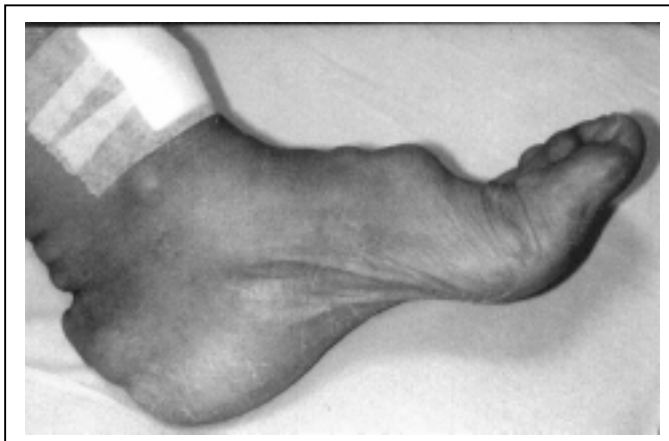


Fig.3. Foot showing Achilles tendon thickening and xanthoma.

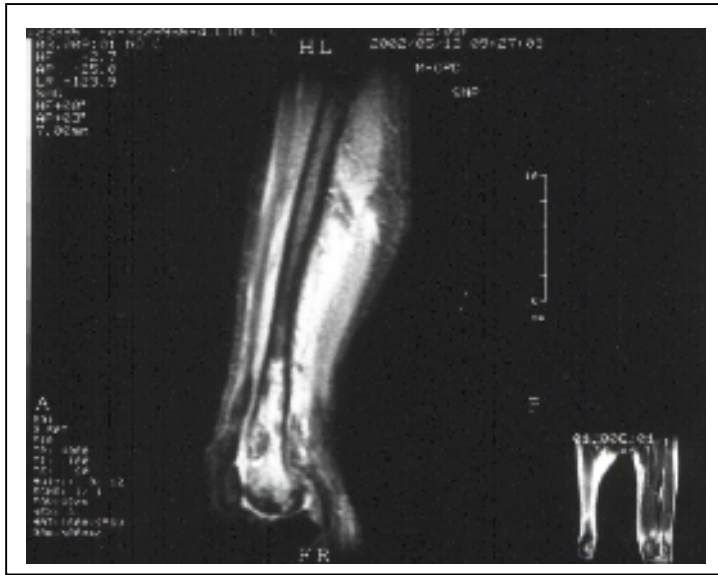

Fig.4.Sagittal STIR image revealed a geographic medullary lesion at the anterior distal left femoral meta-epiphysis, with periosteal thickening and myositis.

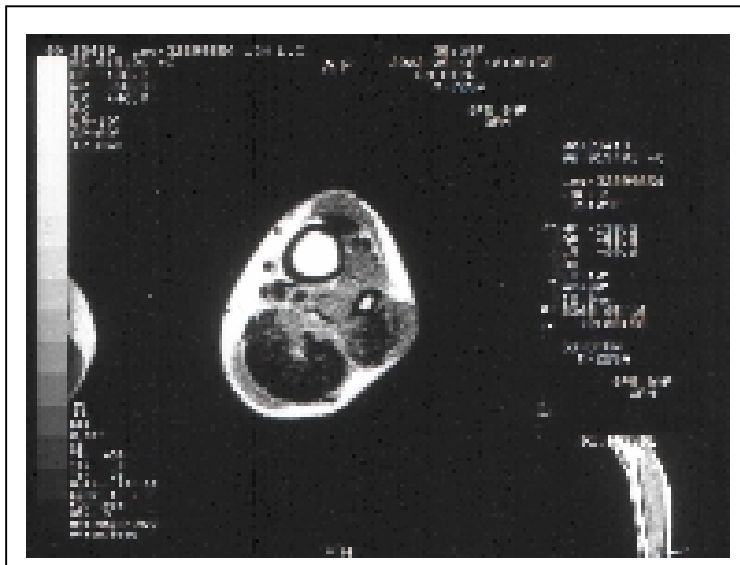


Fig.5.Axial T1-weighted magnetic resonance image showing enlargement of the Achilles and peroneus tendons with diffuse, stippled hypersignal contents representing xanthoma.

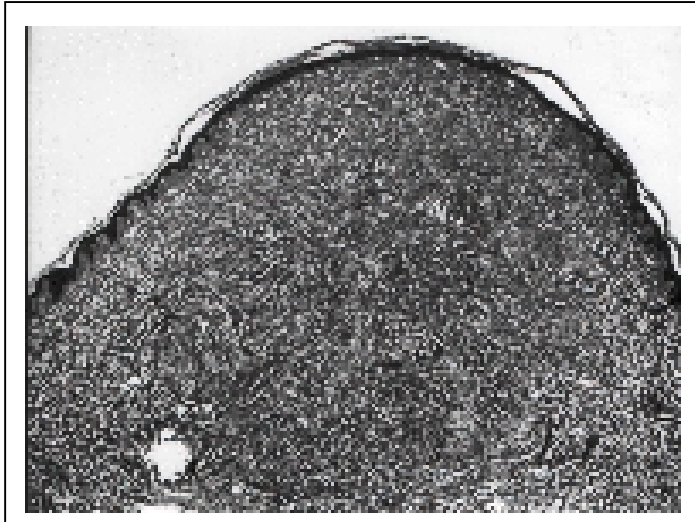


Fig.6.Skin biopsy showing reactive acanthosis of the epidermis, cholesterol clefts and fibrosis (hematoxylin and eosin x 20).



Fig.7.Skin biopsy showing foamy histiocytes, cholesterol clefts and fibrosis (hematoxylin and eosin x 100).