

# A 型主動脈壁內血腫以內科藥物 治療成功之病例報告

林文雄 陳俊延 葉宏一 蔡正河

台北馬偕醫院 心臟內科

## 摘 要

主動脈壁內血腫(aortic intramural hematoma; IMH)一直被認定是主動脈剝離的變異型。傳統上A型主動脈壁內血腫(type A IMH)由於容易惡化的特質，普遍認為以早期開刀治療預後為佳。但近年來陸續有研究論文顯示，因為病理機制不同於主動脈剝離，藥物治療亦有不錯的存活率。一位67歲的女性，有近20年的高血壓病史，因急性胸痛併發昏厥而被送至醫院診治。電腦斷層掃描顯示由升主動脈至降主動脈皆有主動脈壁內血腫。因為病患拒絕開刀治療，故給予抗高血壓藥物嚴格控制血壓。經一星期住院治療，患者胸痛情況緩解且無併發症發生，出院後患者定期追蹤至今已七個月。根據近年來研究報告統計顯示，對於初步影像檢查評為低惡化風險的type A IMH患者，只用藥物治療亦可以考慮。

## Acknowledgement

We would like to thank Dr. Mary Jeanne Buttrey, consulting physician at Mackay Memorial Hospital, Taipei, for her valuable help in revision of the English text.

## References

- Krukenberg E. Beitrage zur Frage des Aneurysma dissecans. *Beitr Pathol Anat Allg Pathol* 1920; 67: 329-51.
- Ganaha F, Miller DC, Sugimoto K, et al. Prognosis of aortic intramural hematoma with and without penetrating atherosclerotic ulcer: a clinical and radiological analysis. *Circulation* 2002; 106: 342-8.
- Robbins RC, McManus RP, Mitchell RS, et al. Management of patients with intramural hematoma of the thoracic aorta. *Circulation* 1993; 88: 1-10.
- Maraj R, Rerkpattanapit P, Jacobs LE, et al. Meta-analysis of 143 reported cases of aortic intramural hematoma. *Am J Cardiol* 2000; 86: 664-8.
- Nienaber CA, von Kodolitsch Y, Petersen B, et al. Intramural hemorrhage of the thoracic aorta: diagnostic and therapeutic implications. *Circulation* 1995; 92: 1465-72.
- Muluk SC, Kaufman JA, Torchiana DF, et al. Diagnosis and treatment of thoracic aortic intramural hematoma. *J Vasc Surg* 1996; 24: 1022-9.
- von Kodolitsch Y, Nienaber CA. Intramural hemorrhage of the thoracic aorta: diagnosis, therapy and prognosis of 209 in vivo diagnosed cases. *Z. Kardiol* 1998; 87: 797-807.
- Kang DH, Song JK, Song MG, et al. Clinical and echocardiographic outcomes of aortic intramural hemorrhage compared with acute aortic dissection. *Am J Cardiol* 1998; 81: 202-6.
- Kaji S, Nishigami K, Akasaka T, et al. Prediction of progression or regression of type A aortic intramural hematoma by computed tomography. *Circulation* 1999; 100: II-281-II-286.
- Vilacosta I, San Roman J, Ferreiros J, et al. Natural history and serial morphology of aortic intramural hematoma: a novel variant of aortic dissection. *Am Heart J* 1997; 134: 495-507.
- Wolff KA, Herold CJ, Tempany CM, et al. Aortic dissection: atypical pattern seen at MR imaging. *Radiology* 1991; 181: 489-95.
- Mohr-Kahaly S, Erbel R, Kearney P, et al. Aortic intramural hemorrhage visualized by transesophageal echocardiography: findings and prognostic implications. *J Am Coll Cardiol* 1994; 23: 658-64.
- Murray JG, Manisali M, Flamm SD, et al. Intramural hematoma of the thoracic aorta: MR image findings and their prognostic implications. *Radiology* 1997; 204: 349-55.
- Evangelista A, Mukherjee D, Mehta RH, et al. Acute intramural hematoma of the aorta: a mystery in evolution *Circulation*. 2005; 111: 1063-70.
- Motoyoshi N, Moizumi Y, Komatsu T, et al. Intramural hematoma and dissection involving ascending aorta: the clinical features and prognosis. *Eur J Cardiothorac Surg* 2003; 24: 237-42.
- Von Kodolitsch Y, Csoz SK, Koschyk DH, et al. Intramural hematoma of the aorta: predictors of progression to dissection and rupture. *Circulation* 2003; 107: 1158-63.
- Oliver TB, Murchison JT, Reid JH. Serial MRI in the management of intramural haemorrhage of the thoracic aorta. *Br J Radiol* 1997; 70: 1288-90.
- Harris KM, Braverman AC, Gutierrez FR, et al. Transesophageal echocardiographic and clinical features of aortic intramural hematoma. *J Thorac Cardiovasc Surg* 1997; 114: 619-26.
- Sueyoshi E, Matsuoka Y, Sakamoto I, et al. Fate of intramural hematoma of the aorta: CT evaluation. *J Comput Assist Tomogr* 1997; 21: 931-8.
- Bolognesi R, Manca C, Tsiatas D, et al. Aortic intramural hematoma: an increasingly recognized aortic disease. *Cardiology* 1998; 89: 178-83.
- Moriyama Y, Yotsumoto G, Kuriwaki K, et al. Intramural hematoma of the thoracic aorta. *Eur J Cardiothorac Surg* 1998; 13: 230-9.
- Shimizu H, Yoshino H, Udagawa H, et al. Prognosis of aortic intramural hemorrhage compared with classic aortic dissection. *Am J Cardiol* 2000; 85: 792-5.
- Nishigami K, Tsuchiya T, Shono H, et al. Disappearance of aortic intramural hematoma and its significance to the prognosis. *Circulation* 2000; 102 : III-243-III-247.
- Song JK, Kim HS, Kang DH, et al. Different clinical features of aortic intramural hematoma versus dissection involving the ascending aorta. *J Am Coll Cardiol* 2001; 37: 1604-10.
- Sohn DW, Jung JW, Oh BH, et al. Should ascending aortic intramural hematoma be treated surgically? *Am J Cardiol* 2001; 87: 1024-6.
- Song JK, Kim HS, Song JM, et al. Outcomes of medically treated patients with aortic intramural hematoma. *Am J Med* 2002; 113: 181-7.
- Moizumi Y, Komatsu T, Motoyoshi N, et al. Management of patients with intramural hematoma involving the ascending aorta. *J Thorac Cardiovasc Surg* 2002; 124: 918-24.
- Keren A, Kim CB, Hu BS, et al. Accuracy of biplane and multiplane transesophageal echocardiography in diagnosis of typical acute aortic dissection and intramural hematoma. *J Am Coll Cardiol* 1996; 28: 627-36.

Table 1. In-hospital mortality in relation to treatment of type A IMH

Reference	Surgical treatment	Medical treatment
	Deaths/Total number of patients	Deaths/Total number of patients
Von Kodolitsch (7)	5/27	13/22
Harris (18)	0/4	2/4
Vilacosta (10)	1/2	2/6
Sueyoshi (19)	0/1	0/1
Bolognesi (20)	0/1	1/3
Moriyama (21)	1/5	0/3
Kaji (9)	0/9	1/13
Shimizu (22)	0/2	3/11
Nishigami (23)	---	1/8
Song (24)	1/6	1/18
Sohn (25)	0/2	0/13
Von Kodolitsch (16)	2/27	6/11
Evangelista (14)	6/14	3/9
Song (26)	---	3/41
Moizumi (27)	1/9	1/24
Keren (28)	0/5	0/1
Kang (8)	0/3	0/4
Total	54/309 (17.5%)	37/192 (19.3%)

tramural hematoma". Studies that did not provide sufficient data of individual patients or included cases of penetrating ulcer were excluded. Reports of meta-analyses with overlapping data bases were also excluded. Finally, we extracted data from 17 studies containing a total of 309 cases of type A IMH. Twelve of these 17 studies (with 211 patients) have already been summarized by von Kodolitsch et al<sup>16</sup>. and we have included 5 additional reports. Surgery was performed in 117 patients (37.9%), and 192 patients (62.1%) were treated medically. There were a total of 54 (17.5%) in-hospital deaths, 17 of 117 (14.5%) patients treated surgically and 37 of 192 (19.3%) treated medically (Table 1). This overall in-hospital mortality rate is very different from that of previous reports<sup>4,7</sup>.

The 30-day mortality after surgery for type A IMH is reported to range from 10% to 50%<sup>3,5,6</sup>, a factor that must be taken into consideration when deciding for or against surgery. The risk of treating this

entity medically is that it may progress to overt type A dissection with cardiac tamponade or aortic rupture, and such progressions carry a poor prognosis. Nienaber et al. stated that such progression usually occurs within 7 days from the onset of IMH<sup>5</sup>. This period could be considered the acute phase of IMH, similar to that of acute aortic dissection. It is therefore important to clarify factors that predict progression during the acute phase, which include: 1. an associated ulcer or intimal erosion<sup>17</sup>; 2. a maximum aortic diameter of 50 mm or greater on initial CT scan<sup>9,23</sup>; 3. persistent or recurrent pain; and 4. maximal aortic wall thickness more than 12 mm in diameter or increasing wall thickness within 2 weeks<sup>9</sup>. Noninvasive imaging therefore provides important prognostic information in acute type A IMH. If initial images do not demonstrate any of the above risk factors for progression, medical treatment may be considered.

The difficulty in assessing the evidence on treatment is that most reports have been of retrospective observational studies with relatively small numbers of patients. In addition, information of long-term survival is limited. Interestingly, von Kodolitsch et al. noted that reports of medical treatment of type A IMH in Asian patients seemed to indicate a better outcome than those in series of Caucasian patients. They strongly recommended surgery as the treatment of choice for type A IMH<sup>16</sup>.

In conclusion, our case demonstrates successful medical treatment of type A IMH, at least over the short term. It is unfortunate that the patient has refused further imaging, but she has remained symptom-free. If initial imaging studies of type A IMH suggest a low risk of progression, medical treatment including a  $\beta$ -blocker may be considered, with frequent follow-up imaging. Should evidence of progression appear, surgery could then be scheduled. Although it may be difficult to collect enough cases, a prospective trial would be welcome to help resolve the question of the best approach to treating type A IMH.

sive type A IMH from the proximal aorta to the level of T11 vertebra and involving the brachiocephalic trunk space (Figure 1). There was no pericardial effusion, hemothorax or hemomediastinum. Because it was a type A IMH with acute symptoms, early surgery was suggested, but the patient and her family refused. She was therefore treated with labetalol, a combined  $\alpha$ - and  $\beta$ - blocker, and captopril, a short-acting angiotensin-converting enzyme inhibitor, to lower her blood pressure. The systolic blood pressure was maintained between 100 and 120 mmHg and the heart rate between 60 and 80 beats per minute. Her chest pain rapidly resolved. Coronary angiography 2 days later revealed patent coronary arteries. On left ventriculography, there was no false lumen or intimal flap seen in the ascending aorta (Figure 2). She was discharged one week later with no evidence of end-organ damage. Her hypertension has remained well controlled on follow-up. She declined a repeat CT, but she has remained asymptomatic for seven months since discharge.

## Discussion

The clinical presentation of IMH is somewhat different from that of aortic dissection. Patients with IMH tend to be older and have more severe initial pain, but they are less likely to have ischemic leg pain or pulse deficits. Patients with IMH are more likely to have hypertension but less likely to have hyperlipidemia. The incidence of preoperative pericardial effusion and aortic regurgitation are significantly lower in patients with intramural hematoma than in those with dissection<sup>15</sup>.

The accepted diagnostic criteria for IMH are: 1. symptoms similar to those of aortic dissection such as severe chest or back pain; 2. absence of a dissection membrane, communication to the aortic lumen, or a Doppler flow signal within the aortic wall; 3. regional circular or crescentic thickening of the aortic wall of  $> 7$  mm with central displacement of intimal calcification<sup>12,18</sup> on TEE; and 4. high attenuation ar-

reas on CT and on T2-weighted MRI (isodense on T1-weighted images) without enhancement after injection of contrast<sup>5,13</sup>. In addition, aortic dissection or penetrating atherosclerotic ulcer must be excluded.

CT is the first choice for diagnosis, especially in an emergency, as it not only detects aortic wall abnormalities but also allows evaluation for the presence of fluid in the pericardium, pleura, and mediastinum. This information is critical in deciding if surgery is mandated. However, the diagnosis must be confirmed by further examination to exclude wall thickening due to atherosclerosis or aortic dissection with a thrombosed false lumen. It generally takes longer and requires more tests to confirm that diagnosis of IMH than that of aortic dissection<sup>14</sup>.

Once the diagnosis is made, the question of treatment remains. As noted above, there is controversy as to whether type A IMH requires immediate surgery, even though that has been the standard recommendation. Without question, early operation is indicated for patients with hemodynamic instability, cardiac tamponade, and impending or frank rupture of the hematoma. Even if medical treatment is attempted, recurrent pain, progression to overt type A dissection, or progressive aortic dilatation are indications for surgery.

However, spontaneous regression of type A IMH has been reported<sup>8-10</sup>. In these cases, patients were treated initially with intensive antihypertensive therapy with an arterial line in place to monitor the blood pressure. A combination of calcium-channel antagonists, nitrates,  $\beta$ - or  $\alpha$ - and  $\beta$ -adrenergic receptor blockers were administered intravenously to maintain the systolic blood pressure between 100 and 120 mm Hg, as with a type B aortic dissection. In the long term, blood pressure control is vital. Von Kodolitsch et al, found that late progression of IMH (regardless of type) and death were more likely if the patient was not treated with  $\beta$ -blockers<sup>16</sup>.

We searched Medline from 1996 to 2005 for studies with the keywords "aortic diseases" and "in-

agement of patients with type A IMH is still controversial. Some authors recommend early surgery for type A IMH because of a poor prognosis with medical treatment alone<sup>4-7</sup>, but others have reported regression of type A IMH without surgical repair<sup>8-10</sup>. In particular, absence of communication with the aortic lumen in terms of flow and pressure may indicate good prognosis<sup>11</sup>.

We report a patient with a type A IMH successfully managed with medical therapy.

## Case Report

A 67-year-old female with a 20-year history of poorly controlled hypertension and a prior CVA presented with near syncope and retrosternal pain radiating to the back for 3 hours. The pain was unrelated to exertion. There was no dyspnea or fever. On physical examination, her blood pressure was 184/96 mmHg and essentially equal in all four extremities. The heart sounds were normal and there was no audible murmur. Cardiac enzymes were within normal limits. Electrocardiography showed a normal sinus rhythm without any abnormalities. On chest x-ray, there was an increased soft tissue density in the left superior mediastinum. Echocardiography showed an increased internal dimension of the ascending aortic

but no intimal flap. Contrast-enhanced computed tomography (CT) of the chest demonstrated an exten-

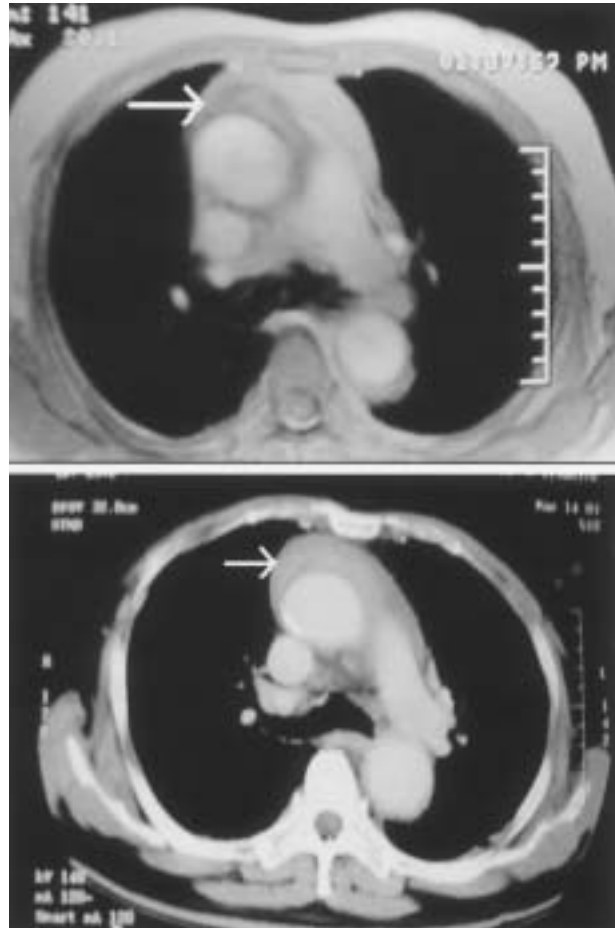


Fig.1. Contrast-enhanced CT revealing an extensive intramural hematoma from the proximal aorta to the level of T11 vertebra.

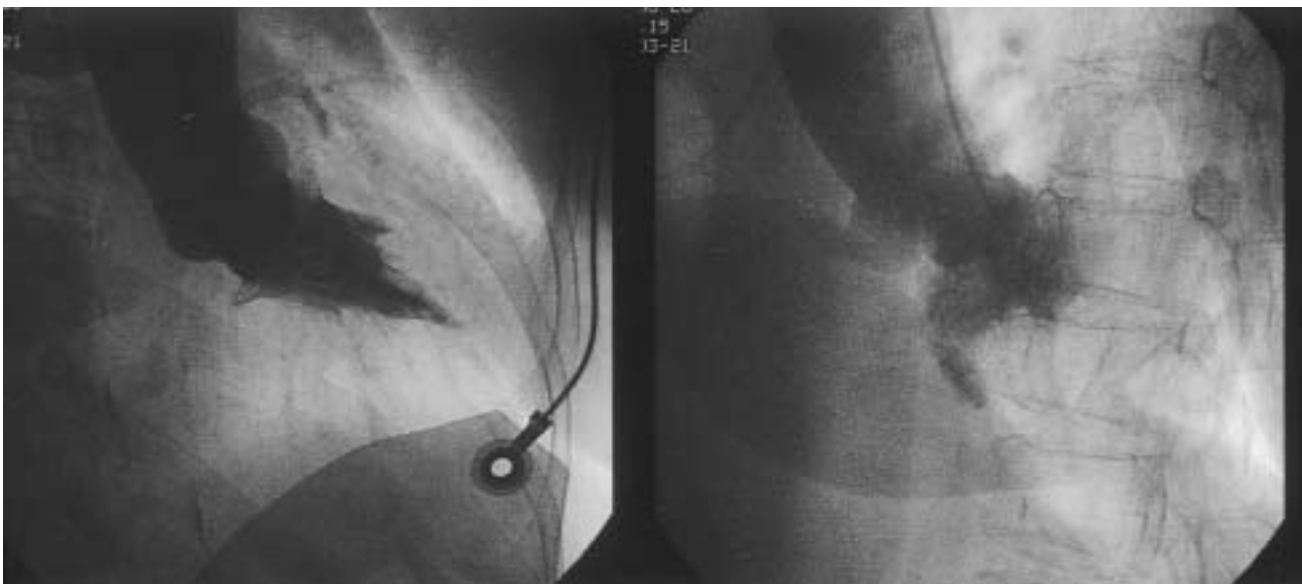

Fig.2. Left ventriculography showing no false lumen or intimal flap in the ascending aorta.

# A Case of Type A Aortic Intramural Hematoma Successfully Managed with Medical Therapy

Wen-Hsiung Lin, Chun-Yen Chen, Hung-I Yeh and Cheng-Ho Tsai

*Division of Cardiology, Department of Internal Medicine, Mackay Memorial Hospital, Taipei, Taiwan.*

## Abstract

Aortic intramural hematoma (IMH) is a variant of aortic dissection. As with type A dissection, early surgery has been recommended for type A IMH because of the high probability of progression. However, the pathology of IMH is distinct from that of aortic dissection, and there have been recent reports of good in-hospital and long-term survival with medical treatment. A 67-year-old female with a 20-year history of poorly controlled hypertension was admitted with severe retrosternal pain. Computed tomography showed a type A aortic IMH from the ascending aorta to the descending aorta. The patient refused emergency surgery, and so she was treated medically to lower her systolic blood pressure. She remained symptom-free after seven months of follow-up. Medical treatment may be acceptable for type A IMH in patients with a low risk of progression. ( J Intern Med Taiwan 2006; 17: 16-21 )

**Key Words** : Aortic disease, Intramural hematoma, Aortic dissection

## Introduction

In autopsy studies, intramural hematoma of the aorta ( IMH ) accounts for 5% to 13% of lesions in all patients with acute aortic syndromes. It was first described in 1920 by Krukenberg et al who viewed it as a variant of aortic dissection caused by bleeding into the outer layers of the media secondary to rupture of the vasa vasorum without a primary intimal

tear<sup>1</sup>. However, over the last 10 years, IMH of the aorta has become increasingly recognized as a pathological entity distinct from aortic dissection<sup>2</sup>. Despite its being diagnosed with increasing frequency, there is no consensus regarding optimal management<sup>3</sup>. As with the Stanford classification of aortic dissection, type A IMH involves the ascending aorta, while type B does not. The latter is usually treated medically, the same as type B aortic dissection<sup>4</sup>. However, man-

---

Correspondence and requests for reprints : Dr. Wen-Hsiung Lin

Address : Division of Cardiology, Department of Internal Medicine, Mackay Memorial Hospital, No. 92, Section 2, Chung-Shan North Road, Taipei 104, Taiwan.