

Management of Mechanical Heart Valve Obstruction

Hsiao-Ching Cheng, Pei-Luen Kang¹, and Shoa-Lin Lin^{2,3}

Division of Cardiology, Department of Medicine, Jiannren Hospital

¹Division of Cardiovascular Surgery,

²Division of Cardiology, Kaohsiung Veterans General Hospital

³National Yang-Ming University,

School of Medicine, Taipei, Taiwan, Republic of China

Abstract

Mechanical valve obstruction is a serious complication of mechanical valve prosthesis. The significant morbidity and mortality associated with this condition warrants rapid diagnostic evaluation. However, diagnosis can be challenging, mainly because of variable clinical presentations and the degree of valvular obstruction. Echocardiography, either transthoracic or transesophageal, and cinefluoroscopy represent the main diagnostic procedures. Treatment with either surgical approach including valvular re-replacement or thrombectomy or medical approach using thrombolysis is two established therapies for prosthetic valve thrombosis. Results from many randomized clinical trials have shown that there is no evidence that either of the two treatment options offers superior results to the other. The purpose of this article is to review the relevant information of prosthetic valve obstruction and provide recommendations for management. (J Intern Med Taiwan 2008; 19: 379-386)

Key Words : Pannus, Mechanical heart valve, Thrombolysis, Thrombosis

Introduction

Mechanical heart valve prostheses have the advantage of longevity over bioprosthetic valves but carry a risk of thrombosis requiring permanent anticoagulation (Bonow, Carabello et al. 2006)^{1,2}. One of the most life-threatening complications of mechani-

cal prostheses is valvular obstruction, with an incidence ranging from 1.0% to 2.7% per patient-year in aortic prostheses and 1.0% to 4.4% per patient-year in mitral prostheses³. Causes of valve obstruction include thrombus formation, pannus formation, or both⁴. Valvular re-replacement is the traditional therapy for mechanical valve thrombosis. Ever since

Correspondence and requests for reprints : Dr. Shoa-Lin Lin

Address : Division of Cardiology, Department of Internal Medicine, Kaohsiung Veterans General Hospital, Kaohsiung Veterans General Hospital, No. 386, Dar-Chung First Road, Kaohsiung City, 813 Taiwan, ROC.

1980s, reports of thrombolytic therapy were published for the treatment of mechanical valve obstruction secondary to thrombosis^{5,6}. Nowadays, thrombolytic therapy has become an alternative to surgery and utilized increasingly as the first line therapy for prosthetic valve obstruction^{7,8}. This report attempts to review the literature and further clarify the issue of management of mechanical valve obstruction.

Etiology of mechanical valve obstruction

Thrombogenicity of mechanical valves remains one of the most common problems despite the improvement in valve design. This risk varies with the type and the site of the prosthesis. Mechanical heart valves at mitral position increases the risk of valvular obstruction almost twice as compared with that at the aortic position. Tilting disc valves and bileaflet valves had a lower incidence of major embolism than caged ball valves^{9,10}. All patients with mechanical valves require anticoagulation. For mechanical prostheses in aortic position, the international normalized ratio (INR) of prothrombin time with warfarin therapy should be maintained between 2.0 and 3.0 for bileaflets valves and Medtronic Hall valves, and between 2.5 and 3.5 for other disc valves and Starr-Edwards valves; for prosthesis in mitral position, the INR should be maintained between 2.5 and 3.5 for all mechanical valves¹. Inadequate anticoagulation has been found in mechanical valve obstruction secondary to thrombus in 25%-79% of cases¹¹⁻¹³. The etiologies of mechanical valve obstruction are thrombus, pannus formation, or both. Distinguishing thrombus from pannus in mechanical valve obstruction is not always possible¹⁴.

Clinical characteristics of pannus or thrombus obstruction

Most reports regarding the incidence of pannus or thrombus in obstructed mechanical prosthesis came from pathologic examinations from 1991 to 2000. Deviri et al¹¹ presented 112 mechanical pros-

thetic valves obstructed by a thrombus (n = 61) or pannus (n = 7), or both (n = 44). Vitale et al³ demonstrated the pathology of mechanical mitral valve obstruction in 87 valves (10 caged-ball valves, 65 tilting-disc valves, and 12 bileaflet valves). The causes of obstruction were pannus formation in 27, generation of thrombus in 21, and both pannus and thrombus in 39.

There are various clinical parameters and diagnostic tests to make the diagnosis of mechanical valve obstruction and aid in distinguishing thrombus from pannus. Onset duration is probably the clue to make the difference between thrombus and pannus in obstructed mechanical prosthesis. Barbetseas et al¹² evaluated 14 patients with prosthetic valve dysfunction and found that the causes of obstructed mechanical prosthetic valves secondary to thrombosis in 14 valves and secondary to pannus ingrowth in 10 valves. The duration of initial onset of discomfort to symptoms of heart failure was more insidious in patients with pannus ingrowth than that of thrombus formation (305 ± 234 days vs 9 ± 6 days; $p = 0.0006$). The interval from valve insertion to reoperation was also longer in the valves with pannus formation (178 ± 52 months vs 62 ± 57 months; $p = 0.0006$). Adequate anticoagulation was more frequent in patients with pannus compared to thrombus (89% vs 21%, $p = 0.0028$). Pannus formation was more common in the aortic position compared to the mitral position¹². Similar presentations in terms of obstruction occurring earlier in thrombus than pannus formation had also reported by others^{4,13}.

Diagnosis of mechanical heart valve obstruction

The clinical evaluation of prosthetic valve obstruction can be performed in the majority of cases with transthoracic echocardiography (TTE) and Doppler echocardiography. For mitral prostheses, a mean gradient > 8 mmHg and an effective area calculated ≤ 1.3 cm² indicate prosthetic valve thrombosis¹⁵. For aortic prostheses, criteria for prosthetic

Table 1. Outcome of thrombolytic therapy for left-sided prosthetic valve obstruction

Source	Patients	Episodes	Site (AV/MV)	CR/PR	Failure (%)	Recurrence (%)	Non-fatal complications (%)	Mortality (%)
Witchitz et al ⁵	12	13	4/9	8/2	3 (23)	1 (7.6)	1 (7.6)	1 (7.6)
Ledain et al ⁶	26	28	12/16	19/3	2 (7)	2 (7)	5 (17.8)	3 (10.7)
Manteiga et al ⁷	13	16	2/14	9/5	2 (12.5)	4 (25)	5 (31.2)	1 (6.2)
Roudaut et al ⁸	110	127	46/79	112	15 (11.8)	24 (18.9)	19 (14.9)	15 (11.8)
Montorsi et al ²⁵	17	17	0/17	12/2	3 (17.6)	2 (11.7)	9 (20.4)	0 (0)
Vitale et al ³⁷	24	24	3/21	23	1 (4.1)	0 (0)	6 (25)	0 (0)
Reddy et al ⁴¹	38	44	4/40	18/21	5 (11.3)	9 (20.4)	4 (9)	5 (11.3)
Gupta et al ³⁴²	110	110	14/96	90/11	9 (8.1)	25 (22.7)	21 (19)	5 (4.5)
Renzulli et al ⁴³	20	20	3/17	19/1	0 (0)	3 (15)	6 (30)	0 (0)
Shapira et al ⁴⁴	12	17	0/12	8/4	5 (29.4)	3 (17.6)	8 (47)	0 (0)

AV= aortic valve, MV= mitral valve, CR= complete response, PR= partial response

valve thrombosis are a mean gradient > 45 mm Hg and an obstructive index (effective orifice area / geometric orifice area) < 0.25¹⁵. For the obstructive index, the effective orifice area is obtained from the continuity equation using Doppler echocardiography. The geometric orifice area is calculated from the prosthetic internal orifice diameter provided by the manufacturer.

Acoustic shadowing originating from the components of the prosthetic valve can severely limit the echocardiographic images. While increased transprosthetic mean pressure gradient as measured by Doppler echocardiography is capable of suggesting the presence of an obstruction¹⁶⁻¹⁹. In a study of 134 patients with mitral prostheses, Fernandes et al identified 95% of patients with valve obstruction using the following criteria: peak E velocity >1.9 m/s, Velocity Time Integral-mitral / Velocity Time Integral-aortic >2.2, and pressure half-time >130 ms¹⁶.

Transesophageal echocardiography (TEE) may provide images superior to those of TTE in detecting mitral valve prosthetic dysfunction²⁰. TEE allows detecting paravalvular leakage and visualizing abnormal echo due to thrombus, which emanating from the atrial surface of the prosthesis^{21,22}. Gueret et al²³ investigated 114 patients with nonobstructive mechan-

ical mitral valve prosthesis by both TTE and TEE. In that setting, TTE did not detect any abnormality in all patients except 1, in whom an abnormal echo was noted on the ventricular side of the prosthesis. TEE appears to be a reliable method to diagnose the formation of thrombi on mechanical mitral valve prosthesis in patients with negative TTE. Barbetseas et al reported that the ultrasound intensity of the mass was higher in pannus than that of thrombus. They also observed that thrombus was larger than pannus and often extended to left atrium of prosthetic mitral valves¹².

Finally, one must highlight the important role of TEE in guiding therapeutic strategy. For left-sided prosthetic valve obstruction, the thrombus size imaged with TEE is a significant independent predictor of outcome. The international PRO-TEE (prosthetic valve thrombolysis- role of transesophageal echocardiography) registry study found that a previous history of cerebrovascular event and a thrombus size >0.8 cm² as one of the major risk factors for systemic embolic complications of thrombolytic therapy²⁴. Any patient with prosthetic valve obstruction who had a thrombus size of >0.8 cm² should receive surgical intervention but not thrombolytic therapy²⁴.

A combination of cineradiography and echocardiography provide an accurate and detailed diagno-

sis to assess valve motion and clot burden^{18,25-29}. Cianciulli TE et al²⁸ reported a prospective study in 221 prosthetic valves (146 aortic, 75 mitral) that highlighted the effectiveness of cinefluoroscopy, which provided valuable information to complement the diagnosis using Doppler echocardiography. When both methods were integrated, the sensitivity, specificity and positive and negative predictive values to distinguish normal from malfunctioning prostheses were 83%, 80%, 89%, and 71%, respectively.

Moreover, Muratori M et al²⁹ demonstrated that the echocardiographic technique had a good concordance with cinefluoroscopy in evaluating the prosthetic leaflets motion. Comparing with cinefluoroscopy data, they found that the opening and closing angles of mitral prostheses were correctly identified by TTE and TEE in 85% and 100%, respectively. For aortic prostheses, opening angles were correctly identified by TTE and TEE, respectively, in 40% and 77% of patients with single-disk prostheses and in 13% and 35% of patients with bileaflet prostheses. Although quantitative evaluation of mitral leaflets motion can be accurately achieved by cinefluoroscopy, however, it is often not useful in differentiating pannus from thrombus.

Management

Operative treatment

Reoperation to replace a mechanical valve is reasonable for patients with thrombosed left-sided prosthetic valve, a large clot burden, or heart failure with New York Heart Association (NYHA) functional class III-IV¹. Variation in peri-operative mortality between reported series reflects differences in clinical condition at the time of surgery, elective or emergency operation and year of operation^{11,13,30-34}. The lowest peri-operative mortality was reportedly 4.7% in a study examining 43 patients in NYHA functional class I-III¹¹. A meta-analysis of seven studies reported that the average risk-unadjusted peri-operative mortality was 14%³⁵. They also described that pa-

tient with higher NYHA functional class would have a greater mortality. In their report, 15 of the 17 deaths (88%) occurred in patients in NYHA functional class III or IV³⁵. Similarly, another report analysis of 549 patients with prosthetic valve dysfunction who undergoing reoperation also disclosed that the hospital mortality was higher in patients in functional class IV compared with those in class II-III (35% vs. 8%)³¹.

Operative procedures included thrombectomy and valve re-replacement. Mechanical thrombectomy reduces total cardiopulmonary bypass time. However, hospital mortality with declotting procedure is not significantly lower than that with conventional valve re-replacement. In the meta-analysis, the recurrent thrombosis rate did not differ significantly between thrombectomy and valve re-replacement³⁵. Early operation usually has a good long term result. Roudaut et al³⁶ had performed mechanical valve replacement in 136 patients with prosthetic valve obstruction, which mainly due to thrombosis formation, their early hospital mortality was 10.3%. All mortality patients were in NYHA functional class III or IV. Therefore, early operation is currently effective and safe, especially in patients in stable hemodynamic condition preoperatively.

In cases of primary mechanical valve dysfunction or extensive pannus formation, valve re-replacement is mandatory³⁷. The decision to thrombectomy or valve re-replacement and choice of new prosthetic valve between bioprosthesis and mechanical valve should be made by surgeon according to personal experiences and morphological findings.

The addition of aspirin (75 to 100 mg per day) to warfarin should be strongly considered after operation unless there is a contraindication to the use of aspirin (example, bleeding or aspirin intolerance)¹.

Thrombolytic treatment

Thrombolysis is reasonable for patients with right-sided prosthetic valve thrombosis with NYHA functional class III-IV or a large clot burden^{1,38}. Thrombolysis has also gained acceptance for treat-

ment of critically ill patients with left-sided prosthetic valve thrombosis, who are assumed to carry high operative risk³⁹. Roudaut⁸ reported a single-center study of 127 instances of prosthetic valve thrombosis with fibrinolysis over a 22-year period. Among these patients, 49 patients (38.6%) were in NYHA functional class IV, 41 patients (32.3%) were in NYHA functional class III and 37 patients (29.2%) were in NYHA functional class I or II. Complete resolution of hemodynamic abnormality was seen in 90 patients (70.9%), partial resolution in 22 patients (17.3%), and failure in 15 patients (11.8%) after treatment with one or more consecutive fibrinolytic agents. The mortality was 15 (11.8%) after thrombolysis. Mortality was significantly higher in patients with NYHA functional class III and IV than in those with NYHA functional class I and II (14 vs 1 patients). Major bleeding occurred in 6 patients (4.7%) and systemic embolisms in 19 patients (15%).

Streptokinase alone, urokinase alone, recombinant tissue-type plasminogen activator (r-TPA) or use of these agents consecutively had been employed^{5-8,39-43}. Numerous thrombolytic protocols have been used. A consensus conference recommended streptokinase (a 250,000-unit bolus in 30 minutes, followed by either an infusion of 100,000-unit per hour) or urokinase (4,400-unit per kilogram per hour) in 1997³⁸. Other reports have described the dose of recombinant tissue-type plasminogen activator, which was usually administered as a 10-mg bolus followed by 90-mg in a continuous 3 hours infusion^{8,43-44}. Ozkan M²⁰ et al used an alternative agent with streptokinase in a slow administration of 60,000 to 100,000-unit per hour for a total of 15 to 24 hours in discrete, successive sessions guided by a serial transesophageal echocardiogram. During thrombolysis therapy, adjunct anticoagulation is not recommended. Administration of warfarin should be discontinued.

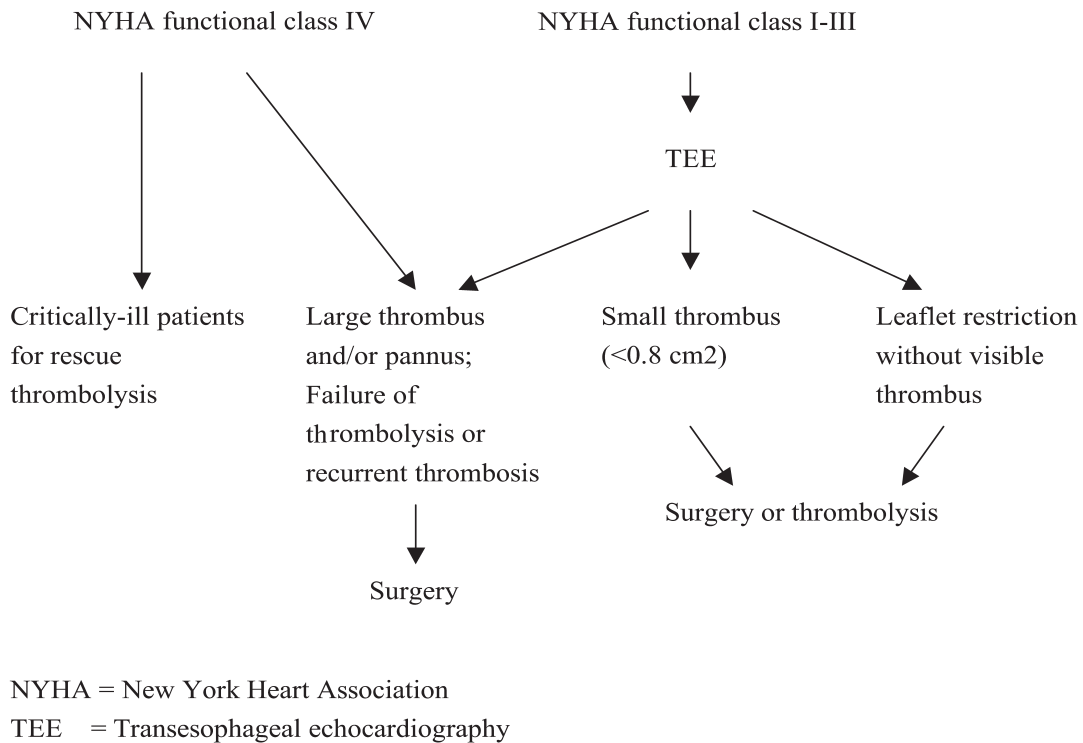


Fig.1. Algorithm for treatment of mechanical heart valve obstruction
 NYHA = New York Heart Association
 TEE = Transesophageal echocardiography

Table 2. Recommendation for treatment of prosthetic valve obstruction

Recommended therapy	Clinical situations
Surgery	Presence of thrombolysis contraindication Critically ill patients (NYHA functional class IV) Large thrombi (>0.8 cm ²) or evidence of pannus formation Failure of thrombolytic therapy Recurrent thrombosis after previous thrombolytic therapy
Thrombolysis	Right-sided prosthetic valve Hemodynamically too unstable to survive operation for rescue Short course of clinical symptoms favoring thrombus formation Prosthetic valve obstruction early after valve replacement (\leq 2 months)
Either surgery or thrombolysis	Small thrombus (<0.8 cm ²) in NYHA functional class I-III

NYHA= New York Heart Association

At the end of thrombolytic therapy, treatment with heparin to achieve aPTT 50 to 80 seconds by continuous infusion is recommended to prevent recurrent thrombosis³⁹. Conversion to oral anticoagulation is targeted to an INR of 2.5 to 3.5 according to the standard recommendations¹.

Use of thrombolysis in New York Heart Association functional class I or II still remains controversial because of the danger of embolic and bleeding complications. Meta-analysis of eleven studies including 365 patients with left-sided prosthetic thrombosis receiving thrombolytic treatment revealed that 5% of the patients suffered severe embolic complications. The overall hospital mortality was 8%, which was the same as that after surgery³⁵. Thus, thrombolysis in NYHA functional class I or II is safe but not a superior therapeutic option, compared with operative treatment. Furthermore, there was a high incidence (20%) of recurrent thrombosis after thrombolysis during follow-up as compared with 3% after valve replacement and 8% after thrombectomy³⁵. The published series of the effects of thrombolysis were presented in Table 1^{5-8,25,41-44}.

Vitale et al⁴³ have opposite view on the policy of carrying out thrombolysis in patients with too unstable hemodynamics to undergo operation. The major consideration is that patients in NYHA functional class III or IV would deteriorate dramatically and they

have an increase risk of bleeding and other complications in subsequent valve replacement procedure if thrombolysis fails. Besides, the results with Re-do operation have demonstrated a considerable improvement over the years. Therefore, some experts prefer surgical intervention to thrombolysis.

Treatments with either surgical approach including valvular re-replacement or thrombectomy or medical approach using thrombolysis are two established therapies for prosthetic valve thrombosis. Figure 1 and Table 2 proposed the recommendations for treatment of patients with prosthetic valve obstruction. However, therapeutic decision-making should take individual patient's specific condition into account.

Conclusion

Reoperation and thrombolysis are the widely accepted options for treatment of mechanical heart valve thrombosis. Surgery is recommended on the following clinical situations: critically ill patients in NYHA functional class IV, thrombolysis contraindicated patients, large thrombi (>0.8 cm²), evidence of pannus formation, failure of thrombolytic therapy, and recurrent thrombosis after previous thrombolytic therapy. Thrombolysis is a favorable treatment on clinical situations such as right-sided prosthetic valve thrombosis, patients in NYHA functional class IV

who are deemed too unstable to survive operation for rescue, short duration of clinical symptoms favoring the presentations of thrombus formation, and prosthetic valve obstruction early after valve replacement surgery. Prosthetic valve obstruction with a small thrombus and stable clinical condition in NYHA functional class I-III can be treated by either surgery or thrombolysis. There is no evidence that either of the two treatment options offers better results than the other. Therapeutic decision-making should take individual patient's specific condition into account.

References

- Bonow RO, Carabello BA, Chatterjee K, et al. ACC/AHA 2006 guidelines for the management of patients with valvular heart disease. : a report of the American College of Cardiology/ American Heart Association Task Force on Practice Guidelines (writing Committee to Revise the 1998 guidelines for the management of patients with valvular heart disease) developed in collaboration with the Society of Cardiovascular Anesthesiologists endorsed by the Society for Cardiovascular Angiography and Interventions and the Society of Thoracic Surgeons. *J Am Coll Cardiol* 2006; 48: e1-148.
- Seiler C. Management and follow up of prosthetic heart valves. *Heart* 2004; 90: 818-24.
- Akins CW. Results with mechanical cardiac valvular prostheses. *Ann Thorac Surg* 1995; 60: 1836-44.
- Vitale N, Renzulli A, Agozzino L, et al. Obstruction of mechanical mitral prostheses: analysis of pathologic findings. *Ann Thorac Surg* 1997; 63: 1101-6.
- Witchitz S, Veyrat C, Moisson P, Scheinman N, Rozenstajn L. Fibrinolytic treatment of thrombus on prosthetic heart valves. *Br Heart J* 1980; 44: 545-54.
- Ledain LD, Ohayon JP, Colle JP, Lorient-Roudaut FM, Roudaut RP, Besse PM. Acute thrombotic obstruction with disc valve prostheses: diagnostic considerations and fibrinolytic treatment. *J Am Coll Cardiol* 1986; 7: 743-51.
- Manteiga R, Carlos Souto J, Altes A, et al. Short-course thrombolysis as the first line of therapy for cardiac valve thrombosis. *J Thorac Cardiovasc Surg* 1998; 115: 780-4.
- Roudaut R, Lafitte S, Roudaut MF, et al. Fibrinolysis of mechanical prosthetic valve thrombosis: a single-center study of 127 cases. *J Am Coll Cardiol* 2003; 41: 653-8.
- Edmunds LH, Jr. Thrombotic and bleeding complications of prosthetic heart valves. *Ann Thorac Surg* 1987; 44: 430-45.
- Cannegieter SC, Rosendaal FR, Briet E. Thromboembolic and bleeding complications in patients with mechanical heart valve prostheses. *Circulation* 1994; 89: 635-41.
- Deviri E, Sareli P, Wisenbaugh T, Cronje SL. Obstruction of mechanical heart valve prostheses: clinical aspects and surgical management. *J Am Coll Cardiol* 1991; 17: 646-50.
- Barbetsseas J, Nagueh SF, Pitsavos C, Toutouzas PK, Quinones MA, Zoghbi WA. Differentiating thrombus from pannus formation in obstructed mechanical prosthetic valves: an evaluation of clinical, transthoracic and transesophageal echocardiographic parameters. *J Am Coll Cardiol* 1998; 32: 1410-7.
- Rizzoli G, Guglielmi C, Toscano G, et al. Reoperations for acute prosthetic thrombosis and pannus: an assessment of rates, relationship and risk. *Eur J Cardiothorac Surg* 1999; 16: 74-80.
- Licata A, Matthai WH, Jr. Evaluating the etiology of mechanical valve obstruction: use of clinical parameters, fluoroscopy, and echocardiography. *Catheter Cardiovasc Interv* 2002; 55: 495-500.
- Roudaut R, Serri K, Lafitte S. Thrombosis of prosthetic heart valves: diagnosis and therapeutic considerations. *Heart* 2007; 93: 137-42.
- Fernandes V, Olmos L, Nagueh SF, Quinones MA, Zoghbi WA. Peak early diastolic velocity rather than pressure half-time is the best index of mechanical prosthetic mitral valve function. *Am J Cardiol* 2002; 89: 704-10.
- Aoyagi S, Nishimi M, Kawano H, et al. Obstruction of St Jude Medical valves in the aortic position: significance of a combination of cineradiography and echocardiography. *J Thorac Cardiovasc Surg* 2000; 120: 142-7.
- Montorsi P, De Bernardi F, Muratori M, Cavoretto D, Pepi M. Role of cine-fluoroscopy, transthoracic, and transesophageal echocardiography in patients with suspected prosthetic heart valve thrombosis. *Am J Cardiol* 2000; 85: 58-64.
- Girard SE, Miller FA, Jr., Orszulak TA, et al. Reoperation for prosthetic aortic valve obstruction in the era of echocardiography: trends in diagnostic testing and comparison with surgical findings. *J Am Coll Cardiol* 2001; 37: 579-84.
- Ozkan M, Kaymaz C, Kirma C, et al. Intravenous thrombolytic treatment of mechanical prosthetic valve thrombosis: a study using serial transesophageal echocardiography. *J Am Coll Cardiol* 2000; 35: 1881-9.
- Khandheria BK, Seward JB, Oh JK, et al. Value and limitations of transesophageal echocardiography in assessment of mitral valve prostheses. *Circulation* 1991; 83: 1956-68.
- Alton ME, Pasierski TJ, Orsinelli DA, Eaton GM, Pearson AC. Comparison of transthoracic and transesophageal echocardiography in evaluation of 47 Starr-Edwards prosthetic valves. *J Am Coll Cardiol* 1992; 20: 1503-11.
- Gueret P, Vignon P, Fournier P, et al. Transesophageal echocardiography for the diagnosis and management of nonobstructive thrombosis of mechanical mitral valve prosthesis. *Circulation* 1995; 91: 103-10.
- Tong AT, Roudaut R, Ozkan M, et al. Transesophageal echocardiography improves risk assessment of thrombolysis of prosthetic valve thrombosis: results of the international PRO-TEE registry. *J Am Coll Cardiol* 2004; 43: 77-84.
- Montorsi P, Cavoretto D, Alimento M, Muratori M, Pepi M. Prosthetic mitral valve thrombosis: can fluoroscopy predict the efficacy of thrombolytic treatment? *Circulation* 2003; 108 Suppl 1: II79-84.
- Montorsi P, Cavoretto D, Repossini A, Bartorelli AL, Guazzi MD. Valve design characteristics and cine-fluoroscopic appearance of five currently available bileaflet prosthetic heart valves. *Am J Card Imaging* 1996; 10: 29-41.
- Montorsi P, Cavoretto D, Parolari A, Muratori M, Alimento M, Pepi M. Diagnosing prosthetic mitral valve thrombosis and the effect of the type of prosthesis. *Am J Cardiol* 2002; 90: 73-6.
- Cianciulli TE, Lax JA, Beck MA, et al. Cinefluoroscopic assessment of mechanical disc prostheses: its value as a comple-

- mentary method to echocardiography. *J Heart Valve Dis* 2005; 14: 664-73.
29. Muratori M, Montorsi P, Teruzzi G, et al. Feasibility and diagnostic accuracy of quantitative assessment of mechanical prostheses leaflet motion by transthoracic and transesophageal echocardiography in suspected prosthetic valve dysfunction. *Am J Cardiol* 2006; 97: 94-100.
 30. Kontos GJ, Jr., Schaff HV, Orszulak TA, Puga FJ, Pluth JR, Danielson GK. Thrombotic obstruction of disc valves: clinical recognition and surgical management. *Ann Thorac Surg* 1989; 48: 60-5.
 31. Bortolotti U, Milano A, Mossuto E, Mazzaro E, Thiene G, Casarotto D. Early and late outcome after reoperation for prosthetic valve dysfunction: analysis of 549 patients during a 26-year period. *J Heart Valve Dis* 1994; 3: 81-7.
 32. Martinell J, Jimenez A, Rabago G, Artiz V, Fraile J, Farre J. Mechanical cardiac valve thrombosis. Is thrombectomy justified? *Circulation* 1991; 84: III70-5.
 33. Piehler JM, Blackstone EH, Bailey KR, et al. Reoperation on prosthetic heart valves. Patient-specific estimates of in-hospital events. *J Thorac Cardiovasc Surg* 1995; 109: 30-48.
 34. Buttard P, Bonnefoy E, Chevalier P, et al. Mechanical cardiac valve thrombosis in patients in critical hemodynamic compromise. *Eur J Cardiothorac Surg* 1997; 11: 710-3.
 35. Hering D, Piper C, Horstkotte D. management of prosthetic valve thrombosis. *Eur Heart J* 2001; 3(Suppl Q): Q22-6.
 36. Roudaut R, Roques X, Lafitte S, et al. Surgery for prosthetic valve obstruction. A single center study of 136 patients. *Eur J Cardiothorac Surg* 2003; 24: 868-72.
 37. Vitale N, Renzulli A, de Luca Tuppiti Schinosa L, Cotrufo M. As originally published in 1994: Prosthetic valve obstruction: thrombolysis versus operation. Updated in 2000. *Ann Thorac Surg* 2000; 70: 2182-3.
 38. Shapira Y, Sagie A, Jortner R, Adler Y, Hirsch R. Thrombosis of bileaflet tricuspid valve prosthesis: clinical spectrum and the role of nonsurgical treatment. *Am Heart J* 1999; 137: 721-5.
 39. Lengyel M, Fuster V, Keltai M, et al. Guidelines for management of left-sided prosthetic valve thrombosis: a role for thrombolytic therapy. Consensus Conference on Prosthetic Valve Thrombosis. *J Am Coll Cardiol* 1997; 30: 1521-6.
 40. Koller PT, Arom KV. Thrombolytic therapy of left-sided prosthetic valve thrombosis. *Chest* 1995; 108: 1683-9.
 41. Reddy NK, Padmanabhan TN, Singh S, et al. Thrombolysis in left-sided prosthetic valve occlusion: immediate and follow-up results. *Ann Thorac Surg* 1994; 58: 462-70; discussion 470-1.
 42. Gupta D, Kothari SS, Bahl VK, et al. Thrombolytic therapy for prosthetic valve thrombosis: short- and long-term results. *Am Heart J* 2000; 140: 906-16.
 43. Renzulli A, Vitale N, Caruso A, et al. Thrombolysis for prosthetic valve thrombosis: indications and results. *J Heart Valve Dis* 1997; 6: 212-8.
 44. Shapira Y, Herz I, Vaturi M, et al. Thrombolysis is an effective and safe therapy in stuck bileaflet mitral valves in the absence of high-risk thrombi. *J Am Coll Cardiol* 2000; 35: 1874-80.

機械性人工心臟瓣膜阻塞的處理

程曉晶 康沛倫¹ 林少琳^{2,3}

健仁醫院 心臟內科

高雄榮民總醫院 ¹心臟外科 ²心臟內科

³國立陽明大學醫學院

摘 要

機械性心臟瓣膜阻塞是發生在機械性心臟瓣膜置換術病人的嚴重併發症之一，快速且正確的診斷及治療與病人的預後及死亡率有關。然而，機械性心臟瓣膜阻塞因多樣的臨床表徵及心臟瓣膜阻塞的程度，造成診斷的困難度和治療的延誤。經胸前或經食道心臟超音波及螢光鏡透視攝影檢查術是主要的診斷工具。機械性心臟瓣膜阻塞的治療則分為手術--包括心臟瓣膜再置換術及血栓切除術，或內科治療--血栓溶解劑二種方式，雖然文獻中已有許多個案報告及大型隨機性的研究來探討此兩種治療，但並無明確證據兩者優劣。此篇文章目的是回溯文獻中對機械性心臟瓣膜阻塞相關的討論並提供治療上的建議。