

Primary Hepatocellular Carcinoma in Ectopic Liver and Later Metastasis to Mother Liver : A Case Report and Review of the Literature

Yuan-Hung Kuo¹, Jing-Houng Wang^{1,2}, Tsung-Hui Hu^{1,2}, and Chuan-Mo Lee^{1,2}

¹*Division of Hepato-Gastroenterology, Department of Internal Medicine,
Chang Gung Memorial Hospital -Kaohsiung Medical Center;*

²*Chang Gung University College of Medicine, Taiwan*

Abstract

We are presenting a case of primary ectopic hepatocellular carcinoma (HCC) that later developed HCC in the mother liver during long-term follow-up. A 64-year-old woman presented with a sudden onset of abdominal pain and internal bleeding. Ectopic HCC was diagnosed by the surgical resection of 2 tumors during laparotomy, which were found near the triangular ligament and lesser curvature of the stomach. Imaging studies revealed no intrahepatic lesion or peritoneal tumors during follow-up. However, 2 small HCCs in the mother liver were detected two years after surgery without peritoneal recurrence. Progressive alpha-fetoprotein elevation was noted despite the complete ablation of the mother liver HCC by image study. Recurrent peritoneal HCC carcinomatosis was detected and confirmed by exploratory laparotomy two years later. The patient died because of disease progression seven years after the peritoneal tumors resection without HCC recurrence in the mother liver. A literature review disclosed 7 ectopic HCC cases, including the present one, who developed mother liver HCC during the follow-up period. Regular serum AFP level monitoring and image studies are recommended for detecting recurrent or metastatic HCC after tumor resection. (J Intern Med Taiwan 2008; 19: 422-427)

Key Words : Adjuvant chemotherapy, Ectopic hepatocellular carcinoma, Tumor rupture

Introduction

Ectopic livers are islands of normal liver parenchyma that have become separated from the main lobes of the liver and are found incidentally by peritoneoscopy, laparotomy, and autopsy. They can occur in various sites near the liver, such as the gallbladder, hepatic ligaments, omentum, retroperitoneum and thorax¹⁻³.

Of the approximately 100 cases of ectopic liver that have been reported, hepatocellular carcinoma (HCC) was detected in 34, with the mother liver free of tumor originally⁴. The carcinogenic factors involved in neoplastic change in the ectopic liver but not the mother liver are not well understood. Of these reported ectopic liver with HCC, 6 patients developed HCC in the mother liver during post-resection follow-up⁵⁻¹⁰. A case of ectopic HCC post-surgical resection with a delayed HCC development in the mother liver during long-term follow-up is presented.

Case report

A 64-year-old woman was sent to the emergency department in April 1999 due to a sudden onset of dull abdominal pain and hypovolemic shock. Her medical history was unremarkable except for a cholecystectomy 4 years previously for gall stones. No regular medication or alcohol abuse was noted. A physical examination revealed a slightly pale conjunctiva and diffused dull abdominal pain without rebounding tenderness. Laboratory studies revealed the following: alanine transaminase (ALT): 50 U/L (normal range: 0-40 U/L), aspartate transaminase (AST): 67 U/L (normal range: 0-37 U/L), hemoglobin : 9.8 g/dl (normal range: M:13.5-17.5, F:14-16 g/dl), platelet count: $280 \times 10^3/\text{mm}^3$ (normal range: $150-400 \times 10^3/\text{mm}^3$), and white blood count: $27.5 \times 10^3/\text{mm}^3$ (normal range: M:3.9-10.6, F:3.5-11 $\times 10^3/\text{mm}^3$). The computed tomography (CT) of the abdomen revealed massive ascites, in which the hemoperitoneum was impressed. Urgent surgical intervention was arranged

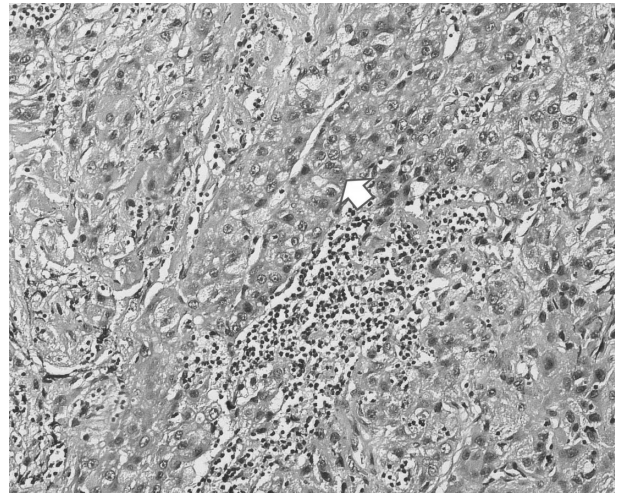


Fig.1. Histological examination (hematoxylin and eosin stain, magnification $\times 100$), showing well-differentiated hepatocellular carcinoma with trabecular architecture (white arrow) and high nucleocytoplasmic (N/C) ratio.

immediately due to hypovolemic shock, upon which two small bleeding tumors were found incidentally. One tumor, measuring approximately $4 \times 2 \times 2 \text{ cm}$ was found on the triangular ligament between the left lobe of the liver and the spleen. Another smaller tumor of about $2 \times 1 \times 1 \text{ cm}$ was found close to the lesser curvature of the stomach. A complete tumor resection was performed. The histology revealed well-differentiated HCC with a trabecular architecture (Fig. 1). Neither intrahepatic lesion nor hepatic cirrhosis was detected during the operation. The immediate post-operative serum Alpha-fetoprotein (AFP) level was 20.9 ng/ml (normal range: $< 5 \text{ ng/ml}$). Negative viral markers, including the hepatitis B virus surface antigen (HBsAg) and antibody to the hepatitis C virus (anti-HCV), were found. The final diagnosis for this patient was ectopic HCC.

However, the progressive elevation of the serum AFP level was detected a year after the tumor resection. No definite peritoneal or liver lesion was demonstrated by the image studies, including liver ultrasonography (US), helical CT, magnetic resonance (MR) imaging and hepatic angiography. At the 28 month-follow-up, a liver US detected 2 small hypoe-

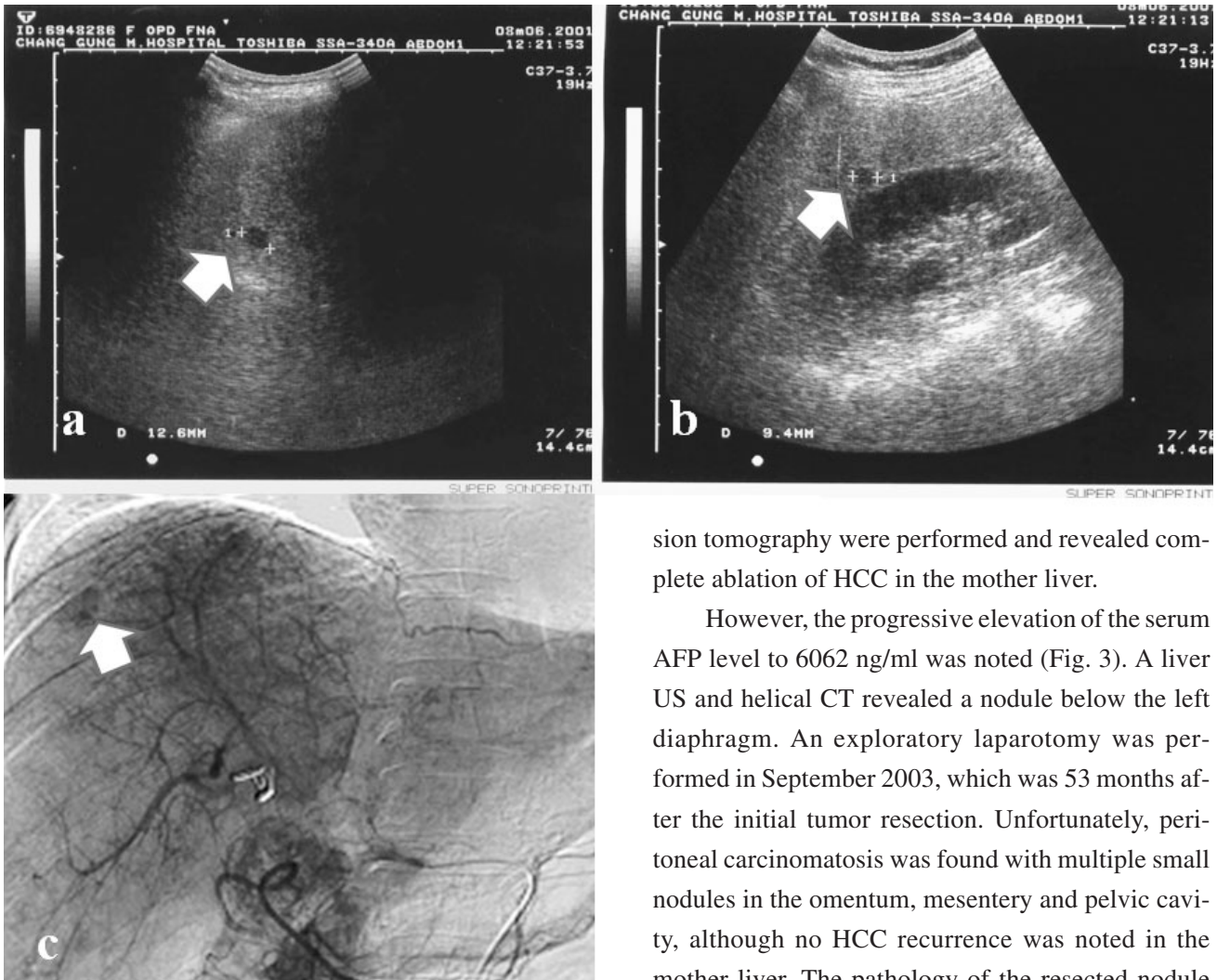


Fig.2.a.Ultrasonography(US) of the abdomen showed a hypoechoic nodule about 0.9 cm at segment 6 (white arrow). b. Another hypoechoic nodule about 1.2 cm at segment 7 (white arrow). c. Celiac angiography showed one hypervascular lesion at segment 7 (white arrow).

choic nodules, measuring 0.9 cm and 1.2 cm on segments 6 and 7, respectively, and a hepatic angiography demonstrated a small hypervascular nodule over segment 7 of the liver (Fig. 2). Fine needle aspiration was performed and the cytology revealed HCC. HCC in mother liver was diagnosed. The patient received a percutaneous ethanol injection and transarterial embolization for HCC in mother liver. Follow-up imaging studies including liver ultrasonography, helical CT, magnetic resonance imaging, and positron emis-

sion tomography were performed and revealed complete ablation of HCC in the mother liver.

However, the progressive elevation of the serum AFP level to 6062 ng/ml was noted (Fig. 3). A liver US and helical CT revealed a nodule below the left diaphragm. An exploratory laparotomy was performed in September 2003, which was 53 months after the initial tumor resection. Unfortunately, peritoneal carcinomatosis was found with multiple small nodules in the omentum, mesentery and pelvic cavity, although no HCC recurrence was noted in the mother liver. The pathology of the resected nodule once again revealed HCC. Hence, primary ectopic HCC with later metastasis in the mother liver and peritoneal carcinomatosis was the preferred diagnosis according to the clinical course. Supportive treatment was offered because of the poor prognosis. The patient died due to disease progression in May 2006, 7 years after the first tumor resection.

Discussion

We are reporting a case of primary ectopic HCC within the abdominal cavity. The presentation of this ectopic HCC was dull abdominal pain and hypovolemic shock due to tumor bleeding. Although intra-abdominal bleeding with obscured origin usually required further investigation, such as an abdominal angiography to confirm the bleeding site, our patient re-

ceived direct surgical intervention due to hemodynamic instability. An ectopic HCC rupture was found accidentally. Most ectopic HCC is detected accidentally, with presentations such as a high AFP level, abdominal pain, or abdominal mass. However, 12% of

reported ectopic HCC present with tumor rupture and bleeding⁴. This specific diagnosis should be considered for patients with internal bleeding and an obscured bleeding site.

The prevalence of ectopic liver was very low, at 0.47% in the laparoscopic series². The ectopic livers appeared to be more prone to hepatocarcinogenesis than the mother liver. Arakawa et al. proposed that ectopic livers are more susceptible to carcinogenesis because they lack the complete functional architecture, such as venous and biliary drainage, which are necessary for excreting viruses or chemical carcinogens. This property enabled far earlier HCC development in the ectopic liver than in the mother liver⁵. Kubota et al. reviewed 34 reported cases of ectopic HCC and showed that the affected patients were older (mean age, 62.5 years) and male predominant (79.4%)⁴. Most patients did not have HCC in the mother liver initially. Cirrhotic liver was found in only 7 patients (20.6%)⁴, while 8% of the patients tested positive for HBsAg and 13.3% tested positive for anti-HCV⁴. Based on the above-mentioned data, it is likely that non-viral factors played a major role in the hepatocarcinogenesis of the ectopic liver.

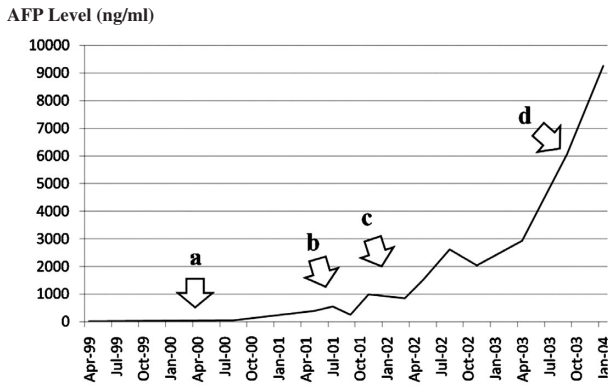


Fig.3. Series of serum AFP level and management. Point a: Apr-00, AFP: 52 ng/ml. Point b: Aug-01, AFP: 547 ng/ml → Liver HCC detection and received TAE & PEI. Point c: Nov-01, AFP: 998 ng/ml → Received TAE; May-02, AFP: 1500 ng/ml → Received TAE; Aug-02, AFP: 2400 ng/ml → Received PEI. Point d: Sep-03, AFP: 6062 ng/ml → Received exploratory laparotomy and carcinoma was confirmed.

Table. Review of primary HCC in ectopic liver and later metastasis to mother liver

Author/Year	Age/Sex	Ectopic HCC			LC	AFP (ng/ml)	HBsAg/HCV Ab	Liver HCC No/FU	FU/prognosis
		Size(cm)	Location	Presentation					
Kawahara ⁶ /1988	64/M	Small, Autopsy	Abdominal cavity	Massive ascites	(-)	117000	NA/NA	Mul/40m	40m/ expired
Kawabata ⁷ /1996	74/M	12, Rec	Left chest wall	Left chest pain	(-)	4116	NA/(+)	Mul/36m	36m/ alive
Arawaka ⁵ /1999	64/M	4, Rec,	Gastic serosa	Occasional finding	(-)	4900	(-)/NA	Mul/12m	15m/ expired
Kim ⁸ /2003	43/F	10, Rec	Between spleen, diaphragm	Occasional finding	(-)	NA	(+)/NA	Mul/7m	23m/ alive
Leone ⁹ /2004	34/F	10, Rec	Between spleen, diaphragm	Intraabdominal bleeding	(-)	NA	(-)/(-)	3/55m	55m/ alive
Shigemori ¹⁰ /2006	72/M	14, Rec	Jejunum	Occasional finding	(-)	NA	(-)/(-)	Mul/2m	12m/ alive
Current case	64/F	4, Rec 2, Rec	Between left lobe, spleen, stomach	Intra-abdominal bleeding	(-)	NA	(-)/(-)	2/28m	85m/ expired

HCC, hepatocellular carcinoma; LC, liver cirrhosis; AFP, alpha-fetoprotein; HBsAg, hepatitis B surface antigen; HCV Ab, antibody to hepatitis C virus; No: number; FU: follow up.

The majority of patients who reported with primary ectopic HCC had good outcomes following the resection of the extrahepatic tumor⁵. However, the development of delayed HCC in the mother liver during post-operative follow-up were reported in 7 cases, including our case⁵⁻¹⁰. (Table) No primary liver tumor was noted for all these 7 cases originally. HCCs were detected in mother livers in 3 patients within the first year during follow-up. One patient presented by Arawaka et al. was found to have multiple pulmonary tumors together with hepatic lesions during the first year follow-up⁵. Leone et al. also described a 34 year-old patient with ovarian and uterus metastasis of HCC within two years after the resection of ectopic HCC⁹. Although a hysterectomy was performed, 3 small tumors were diagnosed in the mother liver 55 months postoperatively. Two other patients had multiple HCCs in mother livers after 3-years' follow-up. The remnant ectopic HCC may have resulted from inadequate resection, and local metastasis might have been the cause of a delayed distant metastasis to the lung. Therefore, recurrent peritoneal HCCs with invasion to mother liver may have the potential to explain the presentation of tumor in mother liver during long-term follow-up.

In our case report, two small HCCs were found in the mother liver 2 years after surgery and were completely ablated by local treatment. Peritoneal carcinomatosis of HCC was demonstrated 4 years after the initial ectopic tumor excision. However, after reviewing all 7 cases, the resection of the extrahepatic tumor alone does not guarantee promising outcomes. There is a possibility that ectopic liver does not necessarily develop in one site. When the visible ectopic tumors were excised, the hepatocarcinogenic process may still progress gradually in some obscure extrahepatic liver tissue. These slowly developed ectopic tumors might invade the local and surrounding tissue, such as the peritoneum, or distantly metastasize to the mother liver and other major organs over time.

Surgical resection is currently the main treat-

ment method for ectopic HCC due to the benign nature of the extrahepatic nodules following resection, as stated in previous studies⁵. However, no report was found regarding the long-term prognosis of patients with ectopic HCC after resection¹¹. Based on our case report, recurrent ectopic HCC could still develop even 3 years after the treatment of the initial lesion⁵⁻¹⁰. Hence, radical wide excision of ectopic HCC, including the adjacent organs, might yield a more promising outcome in these patients.

Huang et al. reported one diaphragmatic ectopic HCC patient receiving 2 courses of chemotherapy 1 month after tumor resection due to the persistent high serum AFP level postoperatively¹². The serum AFP level decreased gradually and the image studies revealed no local recurrence or distal metastasis eight months later. Long-term follow-up is necessary to confirm the effectiveness of postoperative adjuvant chemotherapy.

In conclusion, patients with ectopic HCC do not always have good prognosis after tumor resection. Regular serum AFP level monitoring and image studies are recommended for detecting recurrent or metastatic HCC after initial ectopic HCC resection. If a persistent elevation of serum AFP is detected without the definite finding of a tumor, further management, such as adjuvant chemotherapy, might be considered.

References

1. Watanabe M, Matsuura T, Takatori K, et al. Five cases of ectopic liver and a case of accessory lobe of the liver. *Endoscopy* 1989; 21: 39-42.
2. Asada J, Onji S, Yamashita Y, et al. Ectopic liver observed by peritoneoscopy: report of a case. *Gastroenterol Endosc* 1982; 24: 309-12.
3. Clearfield HR. Embryology, malformation, and malposition of the liver. In: Kaiser MH, Roth JLA, Schaffner F, eds. *Bockus Gastroenterology*, 4th ed. Philadelphia: Saunders, 1985; 2659-65.
4. Keiichi K, Junji K, Kyu R, et al. Ectopic hepatocellular carcinoma arising from pancreas: a case report and review of the literature. *World J Gastroenterol* 2007; 13: 4270-3.
5. Arakawa M, Kimura Y, Sakata K, et al. Propensity of ectopic

- liver to hepatocarcinogenesis: case reports and a review of the literature. *Hepatology* 1999; 29: 57-61.
6. Kawahara E, Kitamura T, Ueda H, et al. Hepatocellular carcinoma arising in the abdominal cavity. An autopsy case of ectopic liver origin. *Acta Pathol Jpn* 1988; 38: 1575-81.
 7. Kawabata K, Adachi Y, Ito T, et al. Occurrence of hepatocellular carcinoma 3 years after resection of a left chest wall tumor which was suspected as ectopic hepatocellular carcinoma. *Kan-Tan-Sui* 1996;32:93-8. [In Japanese]
 8. Kim KA, Park CM, Kim CH, et al. Hepatocellular carcinoma in an ectopic liver: CT findings. *Eur Radiol* 2003; 13(Suppl 4): L45-7.
 9. Leone N, Carrera M, Carucci P, et al. Ectopic liver and hepatocarcinogenesis: report of three cases with four years follow-up. *Eur J Gastroenterol Hepatol* 2004; 16: 731-5.
 10. Shigemori M, Kondo M, Azechi H, et al. A case of ectopic hepatocellular carcinoma in the jejunum. *J Gastroenterol* 2006; 41: 913-8.
 11. Takaaki T, Tadahiko E, Eijirou H, et al. Ectopic hepatocellular carcinoma arising in the bile duct. *J Hepatobiliary Pancreat Surg* 2005; 12: 266-8.
 12. Huang TW, Chan DC, Lee HS, et al. Ectopic Hepatocellular carcinoma of the diaphragm. *Dig Dis Sci* 2007; 52: 1118-20.

異位性肝癌術後長期追蹤發生原發性肝癌： 病例報告與文獻整理

郭垣宏¹ 王景弘^{1,2} 胡琮輝^{1,2} 李全謨^{1,2}

¹高雄長庚醫院 內科部胃腸肝膽科

²長庚大學醫學院 醫學系

摘 要

異位性肝癌(Ectopic HCC)是指異位性肝臟組織發生肝癌，好發於老年男性病人，臨床大多為意外發現，其表現症狀可能有腹痛、腹脹、腹腔內出血合併胎兒蛋白(AFP)上昇。通常異位性肝癌發現時，大部分病人沒有病毒性肝炎、肝硬化或原發性肝癌，目前主要治療方式為手術切除，多數病例報告都有不錯的預後，但缺乏長期追蹤的報告。我們提出一位六十四歲女性病人，本身沒有病毒性肝炎與肝硬化病史，因腹腔內出血性休克，意外在腹膜上發現兩顆破裂的異位性肝癌。經手術切除追蹤一年後，胎兒蛋白(AFP)開始上昇，接受一系列影像學檢查，肝臟與腹腔內並沒有發現腫瘤。直至術後二十八個月，肝臟才發現兩顆小於兩公分肝癌，接受酒精注射與栓塞治療後，肝臟腫瘤沒有復發的現象。但胎兒蛋白(AFP)仍然持續增加，病人接受定期影像監測，直至術後五十三個月，終於發現腹膜有多發性肝癌發生，此時肝臟仍然沒有肝硬化或新的肝癌發生。有鑑於此，病人的臨床診斷推測應為異位性肝癌經手術切除後，長期追蹤發現轉移至肝臟，與腹膜，病人於術後八十五個月因病情惡化死亡。我們整理類似的病例報告後，發現異位性肝癌手術切除後，如果胎兒蛋白(AFP)仍然持續增加，就算影像學檢查沒有證實復發，也應考慮接受更積極的治療(如化學治療)，可能會有較佳的預後。