

Ascites Due to Eosinophilic Gastroenteritis : A Case Report

Lung-Chih Cheng^{1,3}, Gin-Ho Lo¹, Chao-Ming Wu², Ping-I Hsu¹, and Kwok-Hung Lai¹

¹Division of Gastroenterology, Department of Internal Medicine, Kaohsiung Veterans General Hospital, Taiwan;

²Division of Gastroenterology, Department of Internal Medicine, Tian-Sheng Memorial Hospital, Taiwan;

³Division of Gastroenterology, Department of Internal Medicine, Pao-Chien Hospital, Taiwan

Abstract

Eosinophilic gastroenteritis is an uncommon disease characterized by eosinophilic infiltration in the gastrointestinal tract. Kaijser was probably the first to report a patient with eosinophilic gastroenteritis in 1937. Eosinophilic gastroenteritis may involve more than one layer of the gastrointestinal tract. Clinical features depend on the layer and location to be involved. Mucosal involvement leads to protein-losing enteropathy, fecal blood loss, and malabsorption. Involvement of muscle layer often causes obstruction of gastric outlet or small bowel. Subserosal involvement manifests as eosinophilic ascites. We presented a 34-year-old female with progressive ascites and lower leg edema. Eosinophilic gastroenteritis was diagnosed after serial examinations. The patient was treated with prednisolone. The ascites subsided soon after initiation of steroid treatment. (J Intern Med Taiwan 2009; 20: 81-85)

Key Words : Ascites, Eosinophilic gastroenteritis, Eosinophilia, Eosinophilic infiltration

Introduction

Eosinophilic gastroenteritis is an uncommon disease characterized by eosinophilic infiltration in the gastrointestinal tract. Kaijser was probably the first to report a patient with eosinophilic gastroenteritis in 1937¹.

Eosinophilic gastroenteritis may involve serosa of the gastrointestinal tract and result into the development of ascites²⁻⁴. The ascites analysis may

reveal eosinophils to account for a high proportion of white blood cells. We here reported a case of eosinophilic gastroenteritis with predominant symptom of ascites, which was resolved with steroid treatment.

Case report

A 34-year-old Chinese female was admitted for evaluation of progressive abdominal distension and lower leg edema.

She was relatively well in the past until three weeks before this admission. Her chief complaints were upper abdominal pain and frequent loose stool passage. The pain was not related to meal and had no radiation. The abdominal pain was not associated with fever. No obvious body weight loss was noted. Two weeks before admission, she suffered from poor appetite, nausea, abdominal fullness, and swelling of bilateral lower legs. She didn't have past history of liver, renal or gynecological disease. She denied travel history and special food intake before the symptoms happened.

Physical examination disclosed a moderately developed and nourished woman with acute ill-looking. Her consciousness was clear, blood pressure was 145/75 mm-Hg, pulse rate was 94/min, respiratory rate was 20/min, and body temperature was 36.4°C. Abdomen was soft and distended with shifting dullness on percussion.

Laboratory examination disclosed white blood cell count of 13080/mm³ with neutrophils 69%, lymphocytes 5% and eosinophils 25%, hemoglobin of 13.3 g/dL, hematocrit of 38.8%, and platelet 277000/mm³. Total eosinophils count was 5900/mm³. The blood chemistry disclosed albumin 3.2 g/dL, aspartate aminotransferase (AST) 19 U/L, alanine amino-transferase (ALT) 4 U/L, alkaline phosphatase 69 U/L, total bilirubin 0.9 mg/dL, lactate dehydrogenase (LDH) 417 U/L, blood urea nitrogen (BUN) 5 mg/dL, creatinine 0.9 mg/dL, sodium 133 mmol/L, potassium 3.5 mmol/L, fasting blood sugar 91 mg/dL, total cholesterol 147 mg/dL, triglyceride 85 mg/dL. The hepatitis markers and autoantibody test were negative. Stool was negative for occult blood, ova and parasites. Abdominal sonography and computed tomography scan demonstrated markedly increased wall thickening of bowel loops and severe degree of ascites.

Abdominal paracentesis was performed. The gross appearance of ascites was yellowish and turbid. Analysis of ascites disclosed white blood

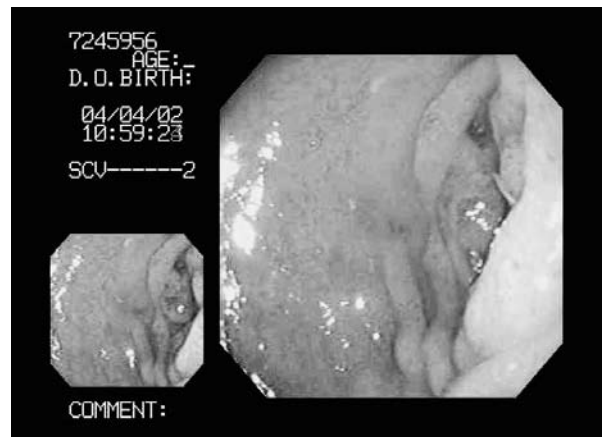


Fig.1. Esophagogastroduodenoscopy disclosed multiple erythematous patches at superior duodenal angle near second portion of duodenum

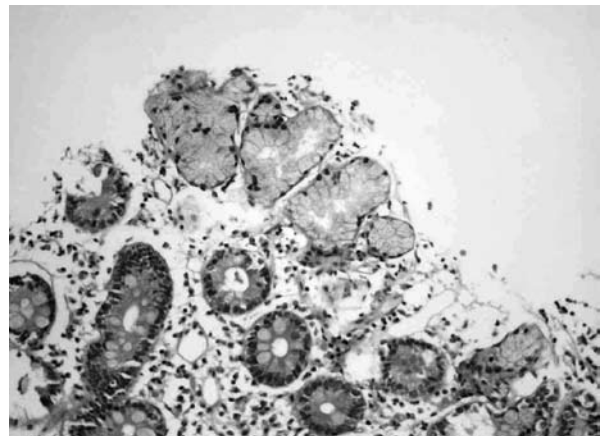


Fig.2. Hematoxylin and eosin stains (100 x) showed duodenal mucosal tissue with marked increase of eosinophilic infiltration in the lamina propria.

cell count of 6700/mm³ (differential count: neutrophils 3%, lymphocytes 4%, eosinophils 90%, monocytes 3%), red blood cells 15350/mm³, LDH 242 U/L, protein 2.3 g/dL, sugar 93 mg/dL. The culture & cytology of ascites were negative finding.

The patient underwent an esophagogastroduodenoscopy (Figure. 1), which demonstrated several linear erythematous patches at fundus and multiple erythematous patches at the superior duodenal angle, near the second portion of duodenum. The histological examination of these duodenal lesions (Figure. 2) showed marked increase of eosinophilic infiltration in the lamina propria. The

sigmoidoscopy revealed several erythematous patches over the sigmoid colon. The histological examination of these colonic lesions also showed increased eosinophilic infiltration in the lamina propria.

These features were consistent with the diagnosis of eosinophilic gastroenteritis with mucosa and subserosa involvement. The patient was thus treated with prednisolone. The dosage of prednisolone for initial treatment was 40 mg/day. The patient's symptoms subsided after steroid treatment for 3 weeks and her steroid dose was successfully tapered within two months.

Discussion

Eosinophilic gastroenteritis is an uncommon disease characterized by eosinophilic infiltration in the gastrointestinal tract. The infiltration may involve one or more layers of the gastrointestinal wall and other abdominal organs^{2,4}.

The pathogenesis of this disease is poorly understood, but speculation has focused on the selective release of eosinophil major proteins leading to the intestinal epithelial damage. Keshavarzian et al. demonstrated that the number of activated degranulated eosinophils in the mucosa correlated with the severity of eosinophilic gastroenteritis⁵. Several reports have pointed to a possible role of allergies to food and other allergens^{6,9}, while other investigators have refuted an allergic reaction as the etiology of this disease⁹⁻¹¹.

Eosinophilic gastroenteritis may involve more than one layer of the gastrointestinal tract. Clinical features depend on which layer and location are involved^{4,6}. Mucosal involvement leads to protein-losing enteropathy, fecal blood loss, and malabsorption. Involvement of muscle layer often causes obstruction of gastric outlet or small bowel. Subserosal involvement manifests as eosinophilic ascites.

In a retrospective study of 40 patients, the

most common symptoms were abdominal pain, nausea, vomiting, and diarrhea. In that study, the percentage of involving mucosal layer, muscle layer and subserosal disease were 58%, 30% and 12% respectively¹².

Talley et al. reported that the patients with subserosal disease could be distinguished from the other two groups by clinical symptoms (abdominal bloating, ascites), higher eosinophils counts, and their dramatic responses to steroid therapy¹². The diagnostic feature of subserosal disease is a marked eosinophilia, up to 88 percent, in the ascitic fluid⁶. Our patient presented with severe ascites. This picture may be confused with cirrhotic ascites or abdominal carcinomatosis. Fortunately, marked eosinophilia in the ascites is an important clue to get the diagnosis of eosinophilic gastroenteritis.

Hypereosinophilia in peripheral blood is present in 20-90% of patients with eosinophilic gastroenteritis^{3,12}. Thus, the absence of peripheral hypereosinophilia should not exclude the diagnosis of eosinophilic gastroenteritis in patients with unexplained gastrointestinal symptoms.

Radiologically, the hallmark of eosinophilic gastroenteritis is the thickening of mucosal folds demonstrated by barium study^{6,11,13}, computerized tomography^{14,15}, or ultrasound^{14,16}, depending on the severity and layer(s) involved¹³. However, similar thickening may also be seen in Menetrier's disease, lymphoma, Crohn's disease, and granulomatous disease. Thus, the thickening of bowel wall is not specific for eosinophilic gastroenteritis. The endoscopic appearance in eosinophilic gastroenteritis is also nonspecific, including erythematous, friable, nodular, and occasional ulcerative changes.

The definite diagnosis of eosinophilic gastroenteritis must fulfill the following criteria: (1) the presence of gastrointestinal symptoms, (2) demonstration of eosinophilic infiltration of one or more areas of the GI tract on biopsy, (3) no evidence of parasitic or extraintestinal disease⁵. The bowel

involvement is often patchy in distribution¹⁷, so more than one panendoscopic examination and biopsies sometimes are necessary to establish the diagnosis. Laparotomy is needed for diagnosis only for those cases complicated with perforation, or involving jejunum and ileum.

In general, the clinical response of eosinophilic gastroenteritis to steroid treatment is usually dramatic^{4,6,11,12,19,20}. The appropriate duration of steroid treatment remains unknown, but improvement usually occurs within two weeks regardless of the layer of bowel involved^{4,18}. But some patients require more prolonged therapy (up to several months) to induce resolution of symptoms¹⁸. Patients with refractory relapsing disease may require long-term low-dose steroids or immunosuppressive therapy.

In conclusion, eosinophilic gastroenteritis presenting as ascites is a rare disease. Eosinophilic gastroenteritis should be suspected in the presence of unexplained chronic or relapsing gastrointestinal symptoms. Ascites analysis is helpful in the diagnosis of eosinophilic gastroenteritis with subserosal involvement. Steroid is the mainstay of therapy.

References

- Kajiser R. ZUR Kenntnis der allergischen Affektion der Verdauungskanal von Standpunkt des Chirurgen aus. *Arch Klin Chir* 1937; 188: 36-64.
- Naylor AR. Eosinophilic gastroenteritis. *Scot Med J* 1990; 35: 163-5.
- Blackshaw AJ, Levison SA. Eosinophilic infiltrates of the gastrointestinal tract. *J Clin Pathol* 1986; 39: 1-7.
- Cello JP. Eosinophilic gastroenteritis: A complex disease entity. *Am J Med* 1979; 67: 1097-104.
- Keshavarzian A, Saverymuttu S, Tai PC, et al. Activated eosinophils in familial eosinophils in familial eosinophilic gastroenteritis. *Gastroenterology* 1985; 88: 1041-9.
- Klein NC, Hargrove RL, Sleisenger MH, Jeffries GH. Eosinophilic gastroenteritis. *Medicine* 1970; 40: 299-319.
- Waldman TA, Wochner RD, Laster L, Gordon RS Jr. Allergic gastroenteropathy, a cause of excessive gastrointestinal protein loss. *N Engl J Med* 1967; 276: 761-9.
- Katz AJ, Goldman H, Grand RJ. Gastric mucosal biopsy in eosinophilic (allergic) gastroenteritis. *Gastroenterology* 1977; 73: 705-6.
- Caldwell JH, Sharma HM, Hurtubise PE, Colwell DL. Eosinophilic gastroenteritis in extreme allergy. Immunopathological comparison with nonallergic gastrointestinal disease. *Gastroenterology* 1979; 77: 560-4.
- Caldwell JH, Tennenbaum JI, Bronstein HA. Serum IgE in eosinophilic gastroenteritis. Response to intestinal challenge in two cases. *N Engl J Med* 1975; 26: 1380-90.
- Leinbach GE, Rubin CE. Eosinophilic gastroenteritis: A simple reaction to food allergens? *Gastroenterology* 1970; 59: 874-89.
- Talley MJ, Shorter RG, Phillips SF, Zinsmeister AR. Eosinophilic gastroenteritis: a clinicopathological study of patients with disease of the mucosa, muscle layer, and subserosal tissues. *Gut* 1990; 31: 45-58.
- MacCarty RL, Talley NJ. Barium studies in diffuse eosinophilic gastroenteritis. *Gastrointest Radiol* 1990; 15: 183-7.
- Rumans MC, Leiberman DA. Eosinophilic gastroenteritis presenting with biliary and duodenal obstruction. *Am J Gastroenterol* 1987; 82: 775-8.
- Tai YG, Liu JD, Lin KY, et al. Eosinophilic gastroenteritis with eosinophilic ascites: Report of a case. *J Formosan Med Assoc* 1990; 89: 901-4.
- Farahvash MJ, Bastani B, Farahvash MR, Irvanlou G. Eosinophilic gastroenteritis presenting with biliary and partial duodenal obstruction. *Am J Gastroenterol* 1990; 85: 1022-4.
- Marshak RH, Lindner A, Maklansky D, Gelb A. Eosinophilic gastroenteritis. *JAMA* 1981; 245: 1677-80.
- Lee CM, Changchien CS, Chen PC, et al. Eosinophilic gastroenteritis: 10 years experience. *Am J Gastroenterol* 1993; 88: 70-4.
- Malaguarnera M, Restuccia N, Pistone G, et al. Eosinophilic gastroenteritis. *Eur J Gastroenterol Hepatol* 1997; 9: 533-7.
- Liacouras CA, Wenner WJ, Brown K, Ruchelli E. Primary eosinophilic esophagitis in children: successful treatment with oral corticosteroids. *J Pediatr Gastroenterol Nutr* 1998; 26: 380-5.

嗜伊紅性胃腸炎引起腹水：病例報告

鄭隆致^{1,3} 羅錦河¹ 吳朝明² 許秉毅¹ 黎國洪¹

¹高雄榮民總醫院 內科部胃腸科

²東港安泰醫院 肝膽腸胃內科

³屏東寶建醫院 胃腸肝膽內科

摘 要

嗜伊紅性胃腸炎是一個少見疾病，是因為嗜伊紅性白血球浸潤腸胃道的黏膜層、肌肉層或漿膜層所引起。此疾病最早是由Kajiser在西元1937年提出。臨床症狀依侵犯消化道的位址、範圍及深淺而有所不同。若侵犯黏膜層會引起蛋白質流失性腸病變、慢性消化道出血及消化道吸收不良。若侵犯肌肉層會引起胃出口阻塞或腸道阻塞。而侵犯到漿膜層時大部份會以腹水的症狀來表現。本病人是34歲女性，因腹痛、腹瀉、腹脹及雙腳水腫來本院就診。腹部超音波及電腦斷層檢查發現腸壁增厚及腹水。週邊血液中嗜伊紅性白血球增加，腹腔放液檢查亦發現嗜伊紅性白血球增加。上消化道及下消化道內視鏡檢查發現有胃、十二指腸及乙狀結腸有發炎性反應，經切片發現在粘膜層有嗜伊紅性白血球浸潤。證實為嗜伊紅性腸胃炎。經給予類固醇治療後，病況改善並於門診繼續追蹤治療。