

Brain Abscess Due to *Listeria Monocytogenes*: A Case Report

Chi-Shun Wu, Sheng-Feng Sung, and Rei-Yeuh Chang¹

*Division of Neurology, ¹Division of Cardiology,
Chia-Yi Christian Hospital, Chia-Yi City, Taiwan*

Abstract

Brain abscess is an uncommon manifestation of central nervous system infection caused by *Listeria (L.) monocytogenes*. We presented a 65-year-old diabetic male patient, who had suffered from intermittent fever with right parieto-occipital throbbing headache for one month. He had been on steroid therapy for anemia for more than two months. No obvious clinical focal neurological deficit was noted on admission. Brain computed tomography (CT) disclosed a brain abscess in the right corona radiata. A transesophageal echocardiogram revealed vegetations on the aortic valves. Blood cultures yielded *L. monocytogenes*. His clinical symptoms resolved after intravenous ampicillin and gentamicin therapy. Serial follow-up brain CT showed decreased size of the brain abscess. *L. monocytogenes* is a rare pathogen of brain abscess. No cases of listerial brain abscess have previously been reported in Taiwan. (J Intern Med Taiwan 2010; 21: 222-226)

Key Words : Brain abscess, Central nervous system infection, Infective endocarditis, *Listeria monocytogenes*

Introduction

Brain abscess is a severe neurological disorder with potential mortality and morbidity. In order to improve clinical prognosis, early diagnosis followed by prompt and appropriate antibiotic therapy is indicated. A wide variety of organisms have previously been identified as causes of brain abscess. However, brain abscess caused by *Listeria (L.) monocytogenes* is rare, being isolated from the aspirated pus in only 0.8% of patients with brain abscess¹. To our knowledge, less than 50 cases have ever been described in literature²⁻⁵. No cases of listerial brain abscess have ever been reported in Taiwan. We herein present a 65-year-old diabetic

male with listerial brain abscess. Good clinical outcome was seen after appropriate intravenous antibiotic therapy.

Case Report

A 65-year-old male patient presented to the emergency room with a chronic right parieto-occipital throbbing headache associated with an intermittent fever for one month. His past medical history was significant for type 2 diabetes mellitus (DM). He had been on oral antidiabetic therapy for several years and his recent HbA1c was 6.2%. He had undergone some dental procedures 3 months previously and had received intermittent antibiotic

therapy for the dental problem. At about the same time, he experienced exertional dyspnea and malaise and was diagnosed as having hemolytic anemia without any identifiable cause in another hospital. His hemoglobin concentration was 7.2 g/dL at that time. He began treatment with oral prednisolone at 45 mg per day with a gradual taper to 10 mg per day in the following two months. One month before admission, he started to suffer from headache and intermittent fever. He was prescribed a nonsteroidal anti-inflammatory drug, but his symptoms remained unchanged.

On physical examination, he was ambulatory with clear consciousness. A fever of 39.4°C was noted. He had tachycardia with a heart rate of 115 beats per minute. His blood pressure was 148/72 mmHg. Acute periodontitis was found by a consulting dentist. His neck was supple and no cardiac murmur was audible. He was well oriented without aphasia or hemineglect. Examinations of the eyegrounds showed no abnormalities. Cranial nerves were all intact and limb muscle power was full. Deep tendon reflexes were equal and plantar reflexes were flexor. Sensory examination was normal. Neither ataxia nor dysmetria was found in finger-to-nose and heel-to-shin tests. A complete blood count revealed a hemoglobin concentration of 11.0 g/dL and a white blood cell count of $7.08 \times 10^9/L$ with 71.5% neutrophils. C-reactive protein was 0.73 mg/dL (0-0.47). His aspartate aminotransferase, alanine aminotransferase, blood urea nitrogen, creatinine, sodium, potassium and chloride levels were all normal. Contrast brain computed tomography (CT) revealed a ring-enhanced lesion with perifocal edema in the right corona radiata (Figs. 1A and 1B).

He was admitted to the medical ward with a tentative diagnosis of brain abscess. Because he suffered from intermittent fever following dental procedures, infective endocarditis was highly suspected. However, no evidence of in-

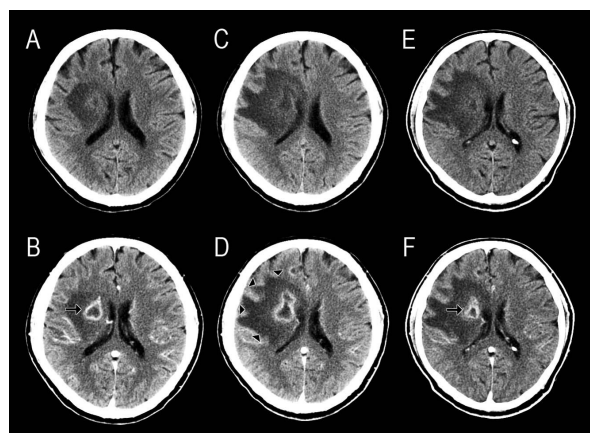


Fig. 1. Serial brain computed tomography (CT) scans with (B, D, F) and without (A, C, E) contrast enhancement show the evolution of the brain abscess. On admission, a ring-enhanced lesion (arrow) with perifocal edema was found in the right corona radiata (A, B). Follow-up brain CT images (C, D) three weeks later revealed expansion of perifocal edema (arrowheads). Five weeks after admission, the brain abscess (arrow) had decreased in size (E, F).

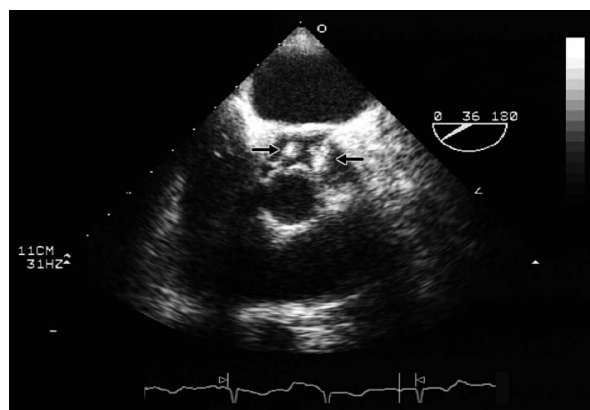


Fig. 2. Transesophageal echocardiogram in transverse plane shows vegetations on the left coronary and the non-coronary cusps of the aortic valves (arrows).

fective endocarditis was found on a transthoracic echocardiogram on the fourth day of hospitalization. So he immediately underwent a transesophageal echocardiogram, which revealed vegetations attached to the left coronary and noncoronary cusps of the aortic valve with mild regurgitation (Fig. 2). Blood culture grew *L. monocytogenes* six days after

admission. He received intravenous ampicillin (2 gm every 4 hours) for 6 weeks in combination with adjuvant intravenous gentamicin (100 mg every 12 hours) during the first 2 weeks. At three weeks after initiation of antibiotic therapy, the patient developed mild left facial weakness and clumsiness in his left limbs, which disappeared within a few days. Follow-up contrast brain CT showed expansion of the perifocal edema surrounding the abscess (Figs. 1C and 1D). At five weeks, the CT revealed decreased size of the brain abscess (Figs. 1E and 1F). Headache and fever subsided completely after the complete course of antibiotic therapy.

Discussion

L. monocytogenes is a gram-positive, facultatively anaerobic, non-spore-forming rod. The organism can be found in soil, water, sewage, and silage, as well as in a wide variety of plants and animals commonly used for human consumption such as cattle, pigs, chicken, and seafood⁶. *L. monocytogenes* is also a facultative intracellular pathogen that uses several remarkable mechanisms for efficiently infecting cells, and escaping eradication by the host⁷. The most important route of transmission is through the ingestion of food contaminated with this bacterium. Although *L. monocytogenes* may cause illness after an incubation period of 11-71 days (median 31 days), the organism is soon cleared from the gastrointestinal tract in most cases⁸.

L. monocytogenes is an important bacterial pathogen in neonates, immunosuppressed patients, the elderly, pregnant women, and sometimes, previously healthy individuals⁹. Clinical syndromes related to listeriosis include sepsis, central nervous system (CNS) infection, endocarditis, gastroenteritis, and localized infection^{10,11}. *L. monocytogenes* has tropism for the brain parenchyma and for the meninges. Meningitis/meningoencephalitis is the most common CNS manifestation^{10,12}. Cerebritis,

which infrequently progresses to brain abscess, is less common. A brainstem encephalitis (rhombencephalitis) caused by *L. monocytogenes* is also well recognized¹³.

The annual incidence of listeriosis varies between 0.3 and 7.5 cases per 1,000,000 people in the US and Europe^{14,15}. Although CNS involvement accounts for 30% to 55 % of patients with listeriosis after the neonatal period, brain abscess is seen in only 1% of all listerial infections¹⁴. The percentage is comparable to another study, in which abscess/cerebritis occurred in 2.7 % of patients with listerial CNS infection¹². Hence the occurrence of brain abscess due to *L. monocytogenes* is very low. In Taiwan, the actual incidence of listeriosis is not known. However, according to studies on adult bacterial meningitis, *L. monocytogenes* accounted for only 0 to 2.3% of episodes of community acquired bacterial meningitis^{16,17}. This proportion was lower than that (11%) found in a similar study in the US¹⁸. In addition, the incidence of neonatal listeriosis in Taiwan was found to be low and the reason was not well established¹⁹.

Most patients with listerial brain abscess were male and were over 50 years old^{2,5}. Altered cell-mediated immunity is a well-recognized risk factor for listerial infection, and those at risk include patients harboring cancer, patients with human immunodeficiency virus infection, and patients receiving corticosteroids or other immunosuppressive therapy¹⁰. Our patient was a 65-year-old diabetic male and was receiving prednisolone treatment. Both corticosteroid therapy and hyperglycemia may have made him more susceptible to listerial infection because of impaired neutrophil function²⁰. DM was identified in 15 to 18 % of patients with listerial brain abscess^{2,5}.

Most patients with listerial brain abscess had a relatively rapid onset of symptoms, with 88% of patients having symptoms for 2 weeks or less². The most common presenting symptoms were fever,

abnormal sensorium and headache. Focal neurological findings included hemiparesis, sixth and/or seventh cranial nerve palsy, aphasia, eye deviation, hemianopsia, etc^{2,12}. Our patient presented with headache and fever in a more indolent manner and had no focal neurological signs even on admission. His minor symptoms might have delayed the diagnosis and proper management. Notably, before the onset of headache, he had suffered from exertional dyspnea, malaise, and anemia, which are common findings for infective endocarditis²¹. We hypothesized that when he contracted *L. monocytogenes* infection he first developed endocarditis. His listerial infection might have been partially treated with oral antibiotics and hence the course of disease was prolonged. Then the persistent endocarditis offered a continuous source of bacteria or infected microemboli, which finally led to the formation of a brain abscess. The microemboli tend to lodge in the capillaries of the distal parts of the superficial arteries in the corticomedullary junction, more frequently in the frontal and parietal regions. As seen in our patient, the brain abscess is located in the white matter of frontal lobe, which is a common site for abscess formation. The continuous use of steroids may have masked the neurological symptoms through its effect on decreasing vasogenic edema surrounding the abscess.

A wide spectrum of antibiotics, including penicillin, ampicillin, trimethoprim/sulfamethoxazole, and vancomycin, are highly effective against *L. monocytogenes*^{2,5,12}. A synergistic effect has been demonstrated when ampicillin was combined with gentamicin⁵. In the presence of positive cultures for *L. monocytogenes*, patients may be treated with antibiotics alone. Surgical drainage is reserved for large abscesses (>2.5 cm), for deeply located abscess in the cerebellum and diencephalon, for well-localized abscess with neurologic deficit, and for identification of the causative agent^{2,12}.

Although, brain abscess due to *L. monocytogenes* is rare, it should be included in the differential diagnosis for patients with altered cell-mediated immunity who present with brain abscess. Because *L. monocytogenes* is usually resistant to cephalosporins, ampicillin should be included in the initial empirical antibiotic regimen for these immunocompromised patients until bacterial culture is available. Successful treatment requires the use of proper antilisterial antibiotics and surgical treatment when appropriate.

References

1. Prasad KN, Mishra AM, Gupta D, Husain N, Husain M, Gupta RK. Analysis of microbial etiology and mortality in patients with brain abscess. *J Infect* 2006; 53: 221-7.
2. Eckburg PB, Montoya JG, Vosti KL. Brain abscess due to *Listeria monocytogenes*: five cases and a review of the literature. *Medicine* 2001; 80: 223-35.
3. Delicou S, Haliotis F, Zachariadou L, Liatsis M, Karavanaki K, Avlonitis S. *Listeria* multiple brain abscesses in an immunocompromised 12-year-old Greek boy: a case report. *Infect Dis Clin Pract* 2007; 15: 351-3.
4. Maezawa Y, Hirasawa A, Abe T, et al. Successful treatment of listerial brain abscess: a case report and literature review. *Intern Med* 2002; 41: 1073-8.
5. Cone LA, Leung MM, Byrd RG, Annunziata GM, Lam RY, Herman BK. Multiple cerebral abscesses because of *Listeria monocytogenes*: three case reports and a literature review of supratentorial listerial brain abscess(es). *Surg Neurol* 2003; 59: 320-8.
6. Buchholz U, Mascola L. Transmission, pathogenesis, and epidemiology of *Listeria monocytogenes*. *Infect Dis Clin Pract* 2001; 10: 34-41.
7. Southwick FS, Purich DL. Intracellular pathogenesis of listeriosis. *N Engl J Med* 1996; 334: 770-6.
8. Linnan MJ, Mascola L, Lou XD, et al. Epidemic listeriosis associated with Mexican-style cheese. *N Engl J Med* 1988; 319: 823-8.
9. Schuchat A, Deaver KA, Wenger JD, et al. Role of foods in sporadic listeriosis. I. Case-control study of dietary risk factors. The *Listeria* Study Group. *JAMA* 1992; 267: 2041-5.
10. Lorber B. Listeriosis. *Clin Infect Dis* 1997; 24: 1-9.
11. Doganay M. Listeriosis: clinical presentation. *FEMS Immunol Med Microbiol* 2003; 35: 173-5.
12. Mylonakis E, Hohmann EL, Calderwood SB. Central nervous system infection with *Listeria monocytogenes*. 33 years' experience at a general hospital and review of 776 episodes from the literature. *Medicine* 1998; 77: 313-36.
13. Armstrong RW, Fung PC. Brainstem encephalitis (rhombencephalitis) due to *Listeria monocytogenes*: case report and review. *Clin Infect Dis* 1993; 16: 689-702.

14. Gellin BG, Broome CV. Listeriosis. JAMA 1989; 261: 1313-20.
15. Almeida GN, Gibbs PA, Hogg TA, Teixeira PC. Listeriosis in Portugal: an existing but under reported infection. BMC Infect Dis 2006; 6: 153.
16. Lu CH, Chang WN, Chang HW. Adult bacterial meningitis in Southern Taiwan: epidemiologic trend and prognostic factors. J Neurol Sci 2000; 15; 182: 36-44.
17. Tang LM, Chen ST, Hsu WC, Lyu RK. Acute bacterial meningitis in adults: a hospital-based epidemiological study. QJM 1999; 92: 719-25.
18. Durand ML, Calderwood SB, Weber DJ, et al. Acute bacterial meningitis in adults. A review of 493 episodes. N Engl J Med 1993; 328: 21-8.
19. Hsieh WS, Tsai LY, Jeng SF, et al. Neonatal listeriosis in Taiwan, 1990-2007. Int J Infect Dis 2009; 13: 193-5.
20. de Marie S. Diseases and drug-related interventions affecting host defence. Eur J Clin Microbiol Infect Dis 1993; 12(Suppl 1): S36-41.
21. Sande RM, Shafran SD. Infective endocarditis: review of 135 cases over 9 years. Clin Infect Dis 1996; 22: 276-86.

單核球增多性李斯特菌腦膿瘍：一病例報告

吳啓順 宋昇峰 張瑞月¹

財團法人嘉義基督教醫院 神經內科 ¹心臟內科

摘 要

腦膿瘍是單核球增多性李斯特菌所導致之中樞神經感染少見的臨床表現，過去在臺灣不曾有單核球增多性李斯特菌腦膿瘍的病例報告。我們報告一位六十五歲男性糖尿病病患，一個月來有間歇性發燒合併右側搏動性頭痛，在此之前曾經因貧血接受類固醇治療兩個月。入院時並無明顯局部神經症狀，腦部電腦斷層檢查顯示右側大腦放射冠有一處腦膿瘍，經食道心臟超音波檢查顯示有主動脈瓣膜贅生物，血液細菌培養呈現單核球增多性李斯特菌。經過使用靜脈抗生素治療後臨床完全消除，後續腦部電腦斷層檢查顯示腦膿瘍已縮小。