

Moyamoya Disease and Thyrotoxic Painless Thyroiditis: A Case Report

Ting-Ting See¹, Siu-Pak Lee², and Chih-Wei Tang²

¹*Division of Endocrinology and Metabolism, Department of Internal Medicine;*

²*Division of Neurology, Department of Internal Medicine, Far Eastern Memorial Hospital, Banciao District, New Taipei City, Taiwan*

Abstract

A few cases of the coexistence of Moyamoya disease and Graves' disease have been reported. But there was no reported case of Moyamoya disease with thyrotoxic painless thyroiditis. A 55-year-old man experienced headache and loss of right temporal vision for one month. He did not have neck pain. Brain MRI showed acute infarct with cortical lamina necrosis at left occipital lobe. Invisible bilateral middle cerebral artery and adjacent collateral vessels were noted. Cerebral angiography was performed and the result was compatible with Moyamoya disease. Thyroid function test showed suppressed TSH and elevated free T4 level. Thyroid autoantibodies were initially negative. Anti-thyroid medication was started for concern of thyroid crisis during acute stroke. Thyroid scintigraphy with Technetium-99 was performed. Thyroid scan uptake was very low. A diagnosis of thyrotoxic painless thyroiditis was confirmed. Two weeks later, patient's thyroid function returned to normal. His anti-thyroid peroxidase antibody became slightly elevated but TSH receptor antibody was still negative. Anti-thyroid treatment was discontinued. Hyperthyroid state was thought to increase cerebral metabolic demand, altered cerebral perfusion and may thus precipitate cerebral ischemia. Development of Graves' disease after painless thyroiditis has been reported. Long term follow up of thyroid function and autoantibodies is necessary for this patient. (J Intern Med Taiwan 2014; 25: 20-24)

Key Words: Moyamoya disease, Painless thyroiditis, Thyrotoxicosis

Introduction

Moyamoya disease is a chronic progressive cerebrovascular disorder characterized by bilateral stenosis or occlusion of the arteries around the circle of Willis with prominent arterial collateral circulation. "Moyamoya" is a Japanese word used to describe the smoky angiographic appearance of the vascular collateral network. Its incidence has

been reported to be higher in the Asian populations. Several studies showed that hyperthyroidism was related to Moyamoya disease and intracranial artery stenosis^{1,2}. It was observed that cerebral infarcts in Moyamoya disease occurred when patients were thyrotoxic. We report a 55-year-old man with Moyamoya disease who developed acute cerebral infarction when he had thyrotoxic painless thyroiditis.

Case Report

A 55-year-old man who was previously healthy with no significant prior medical illness developed headache over the left occipital area accompanied by blurred vision about one month prior to admission.

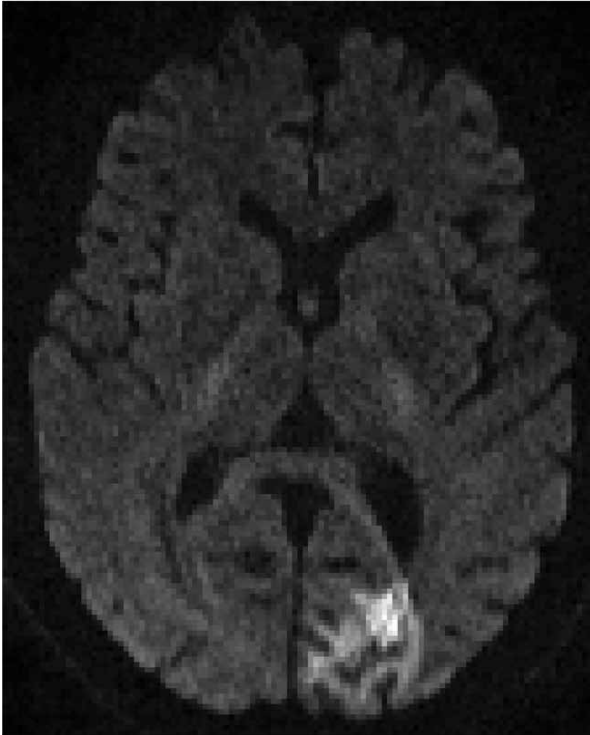


Figure 1. Axial diffusion-weighted MR imaging reveals acute infarction in the left occipital lobe.

He consulted local eye clinic. Ophthalmologic evaluation was normal. He was then referred to our neurologist. At neurology clinic, bilateral abducens nerve palsy was noted. All other cranial nerves evaluations were normal. Brain magnetic resonance imaging (MRI) revealed recent infarct with cortical lamina necrosis at left occipital lobe (Figure 1) and invisible bilateral middle cerebral artery (MCA) with adjacent collateral vessels (Figure 2). He was admitted for further evaluation and management.

On admission, his consciousness was clear and extremities were freely movable. Patient's blood pressure was 143/80 mmHg, heart rate was 104/min and there was no fever. Right temporal visual field defect was noted. His cerebral angiography showed total occlusion of the bilateral anterior cerebral arteries and middle cerebral arteries with distal collaterals and the characteristics “puff of smoke” of Moyamoya disease (Figure 3). Patient had mild exophthalmos but his thyroid was not enlarged. There was no neck pain.

Thyroid function test revealed primary hyperthyroidism. Free T4 level was elevated 3.92 ng/dl (0.8-2 ng/dl) and TSH was suppressed 0.022 uIU/ml (0.3-5 uIU/ml). His initial anti-thyroid peroxidase and TSH receptor antibodies level were within

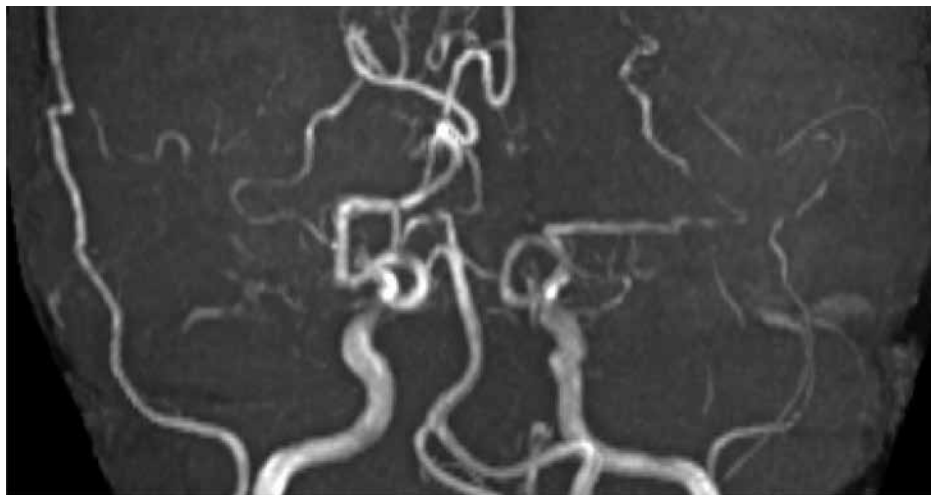


Figure 2. Coronal MR angiography shows near total both middle cerebral arteries (MCAs) occlusion with enlarged right posterior cerebral artery (PCA) collaterals.

normal range. Due to concern for the risk of thyroid crisis during acute stroke, patient was started on anti-thyroid medication with carbimazole and propranolol. In order to clarify if patient's thyrotoxicosis was related to Graves' disease or painless thyroiditis, we ordered Technetium-99m thyroid scintigraphy study. The thyroid scan showed very low uptake of 0.6% (normal 1.6-6%), which was compatible with thyroiditis (Figure 4). Since anti-thyroid treatment was not indicated in thyrotoxic

painless thyroiditis, carbimazole was discontinued. Patient's thyroid function became normal after two weeks. The free T4 was 1.75 ng/dl (0.8-2 ng/dl) and TSH was 0.242 uIU/ml (0.3-5 uIU/ml). His anti-thyroid peroxidase antibody became elevated 55.9 IU/ml (0-35 IU/ml) but TSH receptor antibody was 0.86% (0-15%) which was within normal limit. Patient's thyroid function remained normal after one month. His free T4 was 1.5 ng/dl and his TSH was 0.45 uIU/ml.




Figure 3. Anteroposterior angiography of right common carotid artery (CCA) injection, arterial phase, shows total occlusion of right MCA with enlarged right PCA and external carotid artery (ECA) collaterals [right]. Anteroposterior angiography of left CCA injection, capillary phase, shows total occlusion of the left MCA with prominent lenticulo-lostriate collaterals forming the "puff of smoke" [left].

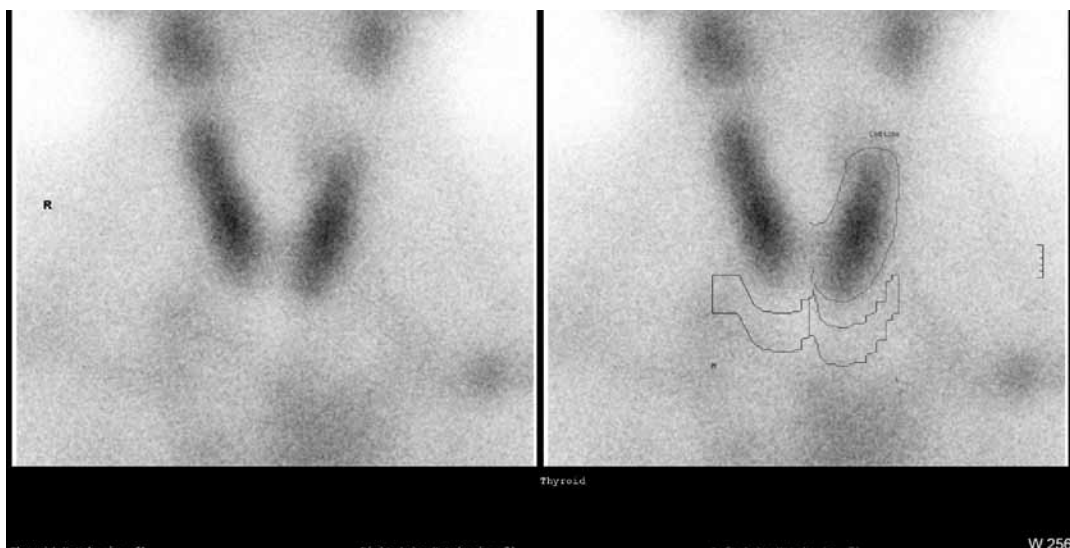


Figure 4. Thyroid scan showed very low thyroid uptake of Tc-99m of 0.6% compatible with thyroiditis.

Discussion

Painless thyroiditis is a transient self-limited thyrotoxicosis. The key finding of painless thyroiditis is a low thyroid scintigraphic uptake.³ The relationship between hyperthyroid state and cerebral vascular diseases has been studied.⁴ Excess thyroid hormone is harmful to arterial walls because it may alter vascular reactivity.⁵ The beta index of stiffness provides a useful diagnostic indicator for detecting asymptomatic common carotid atherosclerosis.⁶ The beta index of stiffness measured at the common carotid artery in hyperthyroid patients was increased significantly and it was thought to be due to the increased stroke volume in thyrotoxicosis. Other studies have shown that hyperthyroid patients have lower large artery elasticity than euthyroid control subjects.⁷ There were several case reports of Graves' thyrotoxicosis and Moyamoya disease.⁵ Some authors have proposed that both Moyamoya and Graves' disease might have a common pathogenic link involving T-cell dysregulation.⁸ Thyroid hormones might augment vascular sensitivity to the sympathetic nervous system and enhance the pathologic process of the arterial wall in moyamoya disease.⁸ It was hypothesized that hyperthyroid state caused an increase in cerebral metabolic demand and altered cerebral perfusion.⁹ It is possible that the hyperthyroid state as a result of the painless thyroiditis in this patient may increase the cerebral metabolic demand to such extent that the compensation of the collateral supply was exceeded and ischemic stroke occurred.

A recent case-control study that included 114 pediatric patients with Moyamoya disease and 114 healthy control subjects has demonstrated that Moyamoya patients have significantly increased thyroid function and autoantibodies.² Thyroid autoantibodies was found to be elevated in young stroke patients with intracranial large artery stenosis.^{1,2} Other disorders associated with Moyamoya disease

are autoimmune diseases that are associated with arteritis of cerebral arteries. Such diseases include Graves' disease, systemic lupus erythematosus, antiphospholipid syndrome, ulcerative colitis, tuberculosis, leptospirosis and postradiation arteritis.⁵ In this patient, a repeated study of anti-thyroid peroxidase antibody was slightly elevated. This elevation of antibody is commonly associated with autoimmune thyroiditis. There have been reported cases of development of Graves' disease following thyrotoxic painless thyroiditis.¹⁰ In a 15-year long term follow up of 124 patients with lymphocytic thyroiditis, about 43% patients had transient spontaneously resolving painless thyroiditis.¹¹ Therefore increased vigilance for the development of subsequent Graves' disease is needed to lessen the risk of recurrent ischemic stroke that may be induced by recurrent thyrotoxicosis in this patient. Surgical revascularization after optimal control of thyrotoxicosis is thought to be an appropriate treatment in patients with Moyamoya disease.¹²

In summary, we reported a case of thyrotoxic painless thyroiditis in a patient of Moyamoya disease with acute cerebral infarction. Hyperthyroidism may increase the risk of cerebral ischemia. Strict control of hyperthyroidism may help to prevent cerebral ischemia in such patients. Thyroid function and autoantibodies should be checked in patients with Moyamoya disease.

References

1. Shi Z, Zhang X, Chen Z, Liebeskind DS, Lou M. Elevated thyroid autoantibodies and intracranial stenosis in stroke at an early age. *Int J Stroke* 2013; doi: 10.1111/ijss.12177 [Epub ahead of print].
2. Li H, Z, Zhang ZS, Dog ZN, et al. Increased thyroid function and elevated thyroid autoantibodies in pediatric patients with Moyamoya disease: a case-control study. *Stroke* 2011; 42: 1138-9.
3. Pearce EN, Farwell AP, Braverman LE. Thyroiditis. *N Eng J Med* 2003; 348: 2646-55.
4. Squizzato A, Gerdes VE, Brandjes DP, et al. Thyroid diseases and cerebrovascular disease. *Stroke* 2005; 36: 2302-10.
5. Hsu SW, Chaloupka JC, Fattal D. Rapidly progressive fatal bihemispheric infarction secondary to Moyamoya syndrome

- in association with Graves thyrotoxicosis. *AJNR Am J Neuro-radiol* 2006; 27: 643-7.
6. Lee R, Sung K, Park YM, Yu JJ, Koh YC, Chung S. A case of Moyamoya disease in a girl with thyrotoxicosis. *Yonsei Med J* 2009; 50: 594-8.
 7. Owen PJ, Sabit R, Lazarus JH. Thyroid disease and vascular function. *Thyroid* 2007; 17: 519-24.
 8. Shen AL, Ryu SJ, Lin SK. Concurrent moyamoya disease and Graves' thyrotoxicosis: case report and literature review. *Acta Neurol Taiwan* 2006; 15: 114-9.
 9. Shargorodskt M, Serov S, Gavish D, Leibovitz E, Harpaz D, Zimlichman R. Long term thyrotropin-suppressive therapy with levothyroxine impairs small and large artery elasticity and increases left ventricular mass in patients with thyroid carcinoma. *Thyroid* 2006; 16: 381-6.
 10. Sarlis NJ, Brucker-Davis F, Swift JP, Tahara K, Kohn LD. Graves' disease following thyrotoxic painless thyroids. Analysis of antibody activities against the thyrotropin receptor in two cases. *Thyroid* 1997; 6: 829-36.
 11. Nikolai TF, Coombs GJ, McKenzie AK. Lymphocytic thyroiditis with spontaneously resolving hyperthyroidism and subacute thyroiditis. Long-term follow-up. *Arch Intern Med* 1981; 141: 1455-8.
 12. Im SH, Oh K, Kwon OK, Kim JE, Han DH. Moyamoya disease associated with Graves disease: special consideration regarding clinical significance and management. *J Neurosurg* 2005; 102: 1013-7.

毛毛樣腦血管病變與甲亢性無痛性甲狀腺炎： 一病例報告

施婷婷¹ 李少白² 唐志威²

亞東紀念醫院 ¹內科部新陳代謝科 ²神經內科

摘 要

文獻有報告少數毛毛樣腦血管病變與葛瑞夫茲氏症有關聯之個案，但尚無與無痛性甲狀腺炎有關之報告。一位55歲男性主訴頭痛及右邊視力缺損一個月。患者並沒有頸部疼痛之症狀。腦部磁振造影發現於左枕葉有急性腦血管栓塞。患者兩側的中大腦動脈並不存在，兩側有不少的側支血管。腦部血管攝影診斷為毛毛樣腦血管病變，患者的甲狀腺功能為原發性的甲狀腺亢進，但其甲狀腺抗體為陰性。為了避免患者在急性中風時併發甲狀腺風暴，我們先給予抗甲狀腺藥物治療。甲狀腺得-99的核子掃描呈現非常低的同位素吸收率，因此診斷為無痛性甲狀腺炎。抗甲狀腺藥物於使用兩週後停用。當時甲狀腺功能已恢復正常，抗甲狀腺過氧化酶抗體卻略為升高，但其甲狀腺激素受器抗體仍為陰性。甲狀腺功能亢進時，腦組織的代謝需求增加，導致其腦部側支血管無法負荷。文獻有報告無痛性甲狀腺炎後可續發葛瑞夫茲氏症，因此有必要定期追蹤患者的甲狀腺功能及抗體。