

Complete Recovery from Dasatinib-induced Pulmonary Arterial Hypertension after Successful Discontinuation of Tyrosine Kinase Inhibitor in A Case of Chronic Myeloid Leukemia

En-Jie Shih^{1,2}, Shih-Hsien Sung^{1,3}, and Jyh-Pyng Gau^{1,4}

¹Faculty of Medicine, National Yang-Ming University, Taipei, Taiwan;

²Department of Medical Education, ³Division of Cardiology, ⁴Division of Hematology, Department of Medicine, Taipei Veterans General Hospital, Taipei, Taiwan

Abstract

Chronic myeloid leukemia could be treated by tyrosine kinase inhibitor successfully. However, a few rare but lethal adverse reactions have been reported. In cases of dasatinib-induced pulmonary arterial hypertension (PAH), the majority generally recovers incompletely and needs alternative TKIs for CML treatment. A 34-year-old woman diagnosed with chronic myeloid leukemia (CML) had taken dasatinib for more than two years. Before dasatinib, she had been under nilotinib treatment for two years, achieving complete molecular response at sixth months, but with persistent hyperbilirubinemia and epigastric discomfort. Twenty months after shifting to dasatinib, she began to experience shortness of breath. Severe pulmonary arterial hypertension was subsequently diagnosed. After withdrawal of dasatinib, the PAH thoroughly resolved. Moreover, complete molecular response was maintained for more than two years without additional tyrosine kinase inhibitor (TKIs) administration. The strength of our case is that the patient fully recovered from the dasatinib-induced severe PAH and kept complete molecular response without taking other TKIs. Early detection of the adverse effect of dasatinib is important for better outcomes. (J Intern Med Taiwan 2019; 30: 161-165)

Key Words: Chronic myeloid leukemia, Dasatinib, Pulmonary arterial hypertension, Tyrosine kinase inhibitor

Introduction

Patients with chronic myeloid leukemia (CML) are administered with tyrosine kinase inhibitors (TKIs) to extend their life expectancy as to that of the general population^{1,2,3}. Subsequently, reducing the side effects of TKI also becomes equally important. The second-generation TKIs, such as nilotinib

and dasatinib, are treatment options with better outcomes comparing to first-generation TKI, imatinib¹. Several studies have reported the hematologic and non-hematologic adverse effects of these TKIs^{1,4,5}. Pulmonary arterial hypertension (PAH) is one of the uncommon but severe cardiovascular complications related to dasatinib⁶⁻¹². Understanding the possibility of occurrence and signs of PAH is neces-

sary for early diagnosis and management. In addition, most of the cases of dasatinib-induced PAH could only recover partially and another TKI for further CML treatment is usually necessary. Here, we report a case of CML developing critical PAH after dasatinib therapy, and the patient achieved complete recovery after drug discontinuation.

Case report

A 34-year-old woman presenting with marked leukocytosis of 465,000/ μ L and a differential of blast less than 10% was diagnosed with chronic myeloid leukemia in June 2011. Philadelphia chromosome, t(9;22) (q43;q11.2), and BCR-ABL fusion gene with a subtype of p210 b3a2 were noted. She was then prescribed with nilotinib 300 mg twice daily. Because of the adverse effects of hyperbilirubinemia and persistent epigastric discomfort, she was switched to dasatinib therapy and her total bilirubin level decreased from 2.24 mg/dl to a normal level thereafter. In addition, the patient achieved the hematologic goal within three months with TKI therapy, the molecular response was up to 4.5 log reduction in BCR-ABL transcript level at 6 months.

One and a half years after dasatinib therapy, the patient experienced progressively exertional dyspnea. Because of the New York Heart Association (NYHA) functional class III symptoms, jugular

vein engorgement, and accentuated P2 on auscultation, she underwent echocardiogram, revealing an estimated right ventricular systolic pressure (RVSP) of 111 mmHg, dilated right ventricle and right atrium, and normal left ventricular systolic function (Figure 1A and B). Right heart catheterization illustrated pulmonary arterial wedge pressure of 11 mmHg, mean pulmonary arterial pressure of 30 mmHg, cardiac index of 2.72 L/min/m², and negative vasoreactivity test. Further examinations, including pulmonary function test, arterial blood gas analysis, and chest computed tomography scan confirmed the diagnosis of PAH. The serologic studies did not show evidence of human immunodeficiency virus infection, viral hepatitis, or connective tissue disease.

Dasatinib was withdrawn, and the patient was put on sildenafil therapy under the impression of drug-related PAH. The patient's symptoms significantly improved to NYHA functional class I, and her follow-up echocardiogram at the fourth month showed normal RVSP, and normalized right ventricular size and function (Figures 2A and B). Sildenafil was then tapered, and further echocardiography up to 2 years all showed normal RVSP and normal right ventricular performance. In addition, her CML remained in complete molecular response without additional TKIs.

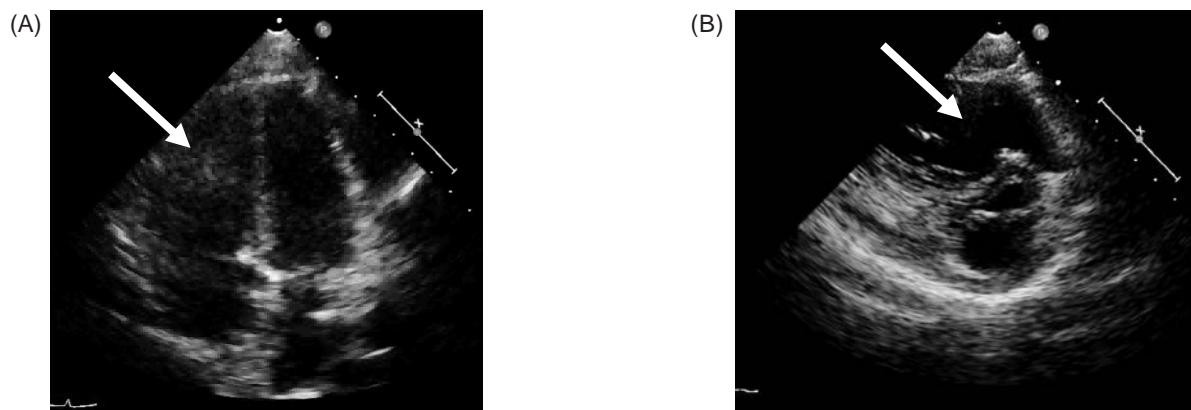


Figure 1. (A) Four-chamber view of the patient's echocardiogram. (B) Short-axis view of the patient's echocardiogram. Echocardiograms of (A) and (B) revealed normal LV function, dilated RV (arrows) and RA, and preserved RV function. LV= left ventricle, RV= right ventricle, RA= right atrium.

Discussion

Before the invention of TKIs, interferon- α (IFN α) and stem cell transplantation (SCT) were two major options to cure CML patients¹. However, IFN α had many unfavorable side effects, such as pancytopenia, flu-like syndromes, and hair loss. On the other side, despite its high cure rate with a 3-year survival rate of more than 80%, SCT has formidable potential complications of graft-versus-host disease. Without any curative attempt, patients on palliative medications of hydroxyurea will have acute leukemia with a median duration of approximately 4.5 years.

Prior to 2001, more than 2 in 3 CML patients died 5 years after they have been diagnosed. Because of TKI administration, the overall survival rate of CML patients now is 89%, and the rate of survival of CML-related death is about 95% within 3 years^{12,13}. Thus, identifying the adverse effects of this agent should be important to improve CML patients' quality of life. Imatinib is the first-generation TKI for CML patients from 2000 to 2005. Since then, second-generation TKIs, such as dasatinib, nilotinib, were introduced with more effective complete cytogenetic response (CCyR), major molecular response (MMR), and favorable event-free survival (EFS)¹. Hence, the current trend of CML treatment is to use second-generation TKIs as a frontline

therapy for certain population for MMR or complete molecular response (CMR)¹⁴.

The adverse effects of TKIs could be classified as hematologic and non-hematologic events. PAH is a rare cardiovascular complication, while the first case of dasatinib-related PAH has been reported in 2009¹⁰. Montani et al. have presented 9 cases of dasatinib-related PAH, and two of them died of cardiac failure⁷. The other patients remained symptomatic persistently after being switched to other TKI drugs. It is suggested that dasatinib has a causative relationship with PAH, which may be fatal and irreversible even after withdrawing dasatinib⁷⁻¹².

Instead of taking TKIs for the rest of CML patients life in the past, physicians began to focus on the time to stop medications^{1,2,15}. However, the safety criteria for discontinuation of TKIs has not yet been established. Several studies targeting withdrawal of imatinib after more than 32 months of treatment indicated 50% of molecular relapse rate within 12 months. In 2016, one research reported that the cumulative incidences of molecular relapse from dasatinib or nilotinib discontinuation was 35% by one year after at least a 3-year therapy². It seems that long-term discontinuation of TKIs seems possible for patients having achieved deep molecular response for a certain period of time.

The strength of our case report is that the patient recovered completely from the dasatinib-

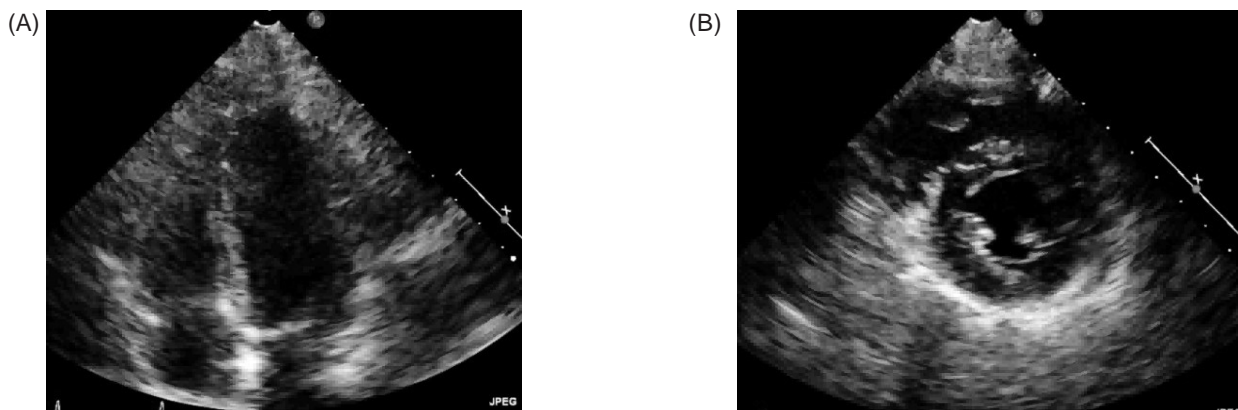


Figure 2. (A) Four-chamber view of the patient's echocardiogram. (B) Short-axis view of the patient's echocardiogram. The images of (A) and (B) show the normal RV size. RV = right ventricle.

induced severe PAH according to the NYHA functional classification and her echocardiogram findings. In addition, she also maintained complete molecular response after discontinuation of dasatinib for more than 2 years without additional TKIs. Physicians should be vigilant on the potential complication of dasatinib-induced PAH, and early discontinuation of the agent allows the patient to completely recovery.

References

1. Cortes J, Kantarjian H. How I treat newly diagnosed chronic phase CML. *Blood* 2012; 120: 1390-7.
2. Saussele S, Richter J, Hochhaus A, et al. The concept of treatment-free remission in chronic myeloid. *Leukemia* 2016; 30: 1638-47.
3. Riou M, Seferian A, Savale L, et al. Deterioration of pulmonary hypertension and pleural effusion with bosutinib following dasatinib lung toxicity. *Eur Respir J* 2016; 48: 1517-19.
4. Valent P, Hadzijusufovic E, Scherthaner GH, et al. Vascular safety issues in CML patients treated with BCR/ABL1 kinase inhibitors. *Blood* 2015; 125: 901-6.
5. Pasvolsky O, Leader A, Iakobishvili Z, et al. Tyrosine kinase inhibitor associated vascular toxicity in chronic myeloid leukemia. *Cardio-Oncology* 2015; 1: 5.
6. Galie N, Humbert M, Vachiery JL, et al. 2015 ESC/ERS guidelines for the diagnosis and treatment of pulmonary hypertension. *Rev Esp Cardiol (Engl Ed)* 2016; 69: 177.
7. Montani D, Bergot E, Günther S, et al. Pulmonary arterial hypertension in patients treated by dasatinib. *Circulation* 2012; 125: 2128-37.
8. Seegobin K, Babbar A, Ferreira J, et al. A case of worsening pulmonary arterial hypertension and pleural effusions by bosutinib after prior treatment with dasatinib. *Pulm Circ* 2017; 7: 808-12.
9. Guignabert C, Phan C, Seferian A, et al. Dasatinib induces lung vascular toxicity and predisposes to pulmonary hypertension. *J Clin Invest* 2016; 126: 3207-18.
10. Moslehi JJ, Deininger M. Tyrosine kinase inhibitor-associated cardiovascular toxicity in chronic myeloid leukemia. *J Clin Oncol* 2015; 33: 4210-8.
11. Weatherald J, Chaumais MC, Savale L, et al. Long-term outcomes of dasatinib-induced pulmonary arterial hypertension: a population-based study. *Eur Respir J* 2017; 50.
12. Yun S, Anwer F, Vincelette ND. Dasatinib-induced pulmonary hypertension in chronic myelogenous leukaemia. *BMJ Case Rep* 2014; 2014.
13. Rea D, Nicolini FE, Tulliez M, et al. Discontinuation of dasatinib or nilotinib in chronic myeloid leukemia: interim analysis of the STOP 2G-TKI study. *Blood* 2017; 129: 846-54.
14. Mario A, Roberto L, Alessandra L, et al. Young CML Patients Treated Frontline with Imatinib or Second Generation TKIs: Clinical Characteristics and Outcome. *Blood* 2016; 128: 3078.
15. Cortes JE, Saglio G, Kantarjian, HM, et al. Final 5-year study results of DASISION: the dasatinib versus imatinib study in treatment-naive chronic myeloid leukemia patients trial. *J Clin Oncol* 2016; 34: 2333-40.

慢性骨髓性白血病患者服用 dasatinib 導致的肺高壓 在停藥後復原，且不需再服用酪胺酸激酶抑制劑： 病例報告

施恩潔^{1,2} 宋思賢^{1,3} 高志平^{1,4}

¹ 國立陽明大學醫學系

臺北榮民總醫院 ² 教學部 內科部 ³ 心臟科 ⁴ 血液科

摘要

隨著酪胺酸激酶抑制劑的使用，慢性骨髓性白血病患者的壽命有了大幅增長，然而，有些罕見而致命的副作用如 dasatinib 造成的肺高壓，常常導致病人不可逆的傷害，且之後仍需使用他種酪胺酸激酶抑制劑以治療慢性骨髓性白血病。在我們的病例中，病人因及早發現 dasatinib 造成的肺高壓而停藥並接受治療，之後成功的完全恢復，且不須再使用其他酪胺酸激酶抑制劑。